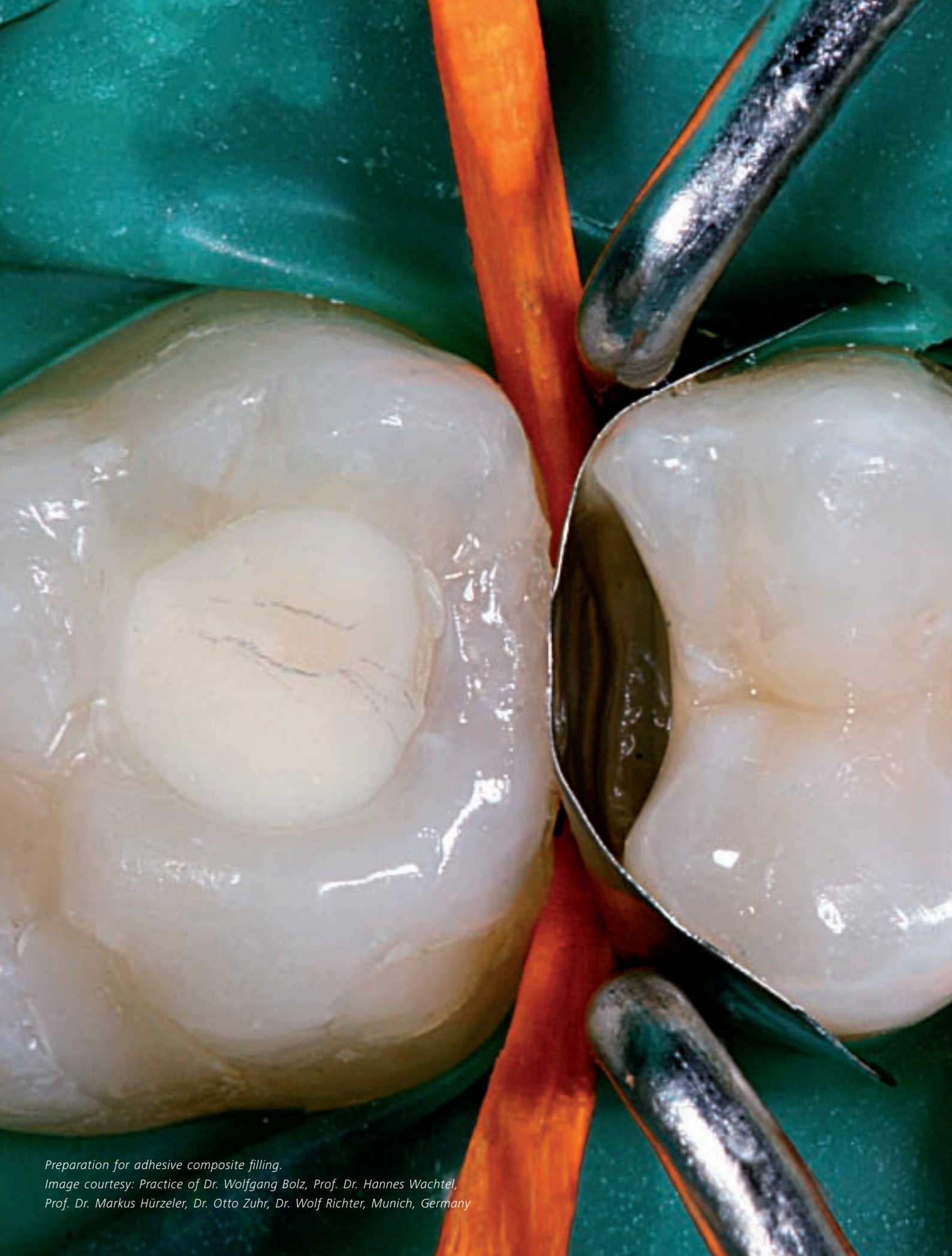

The Microscope in Dentistry

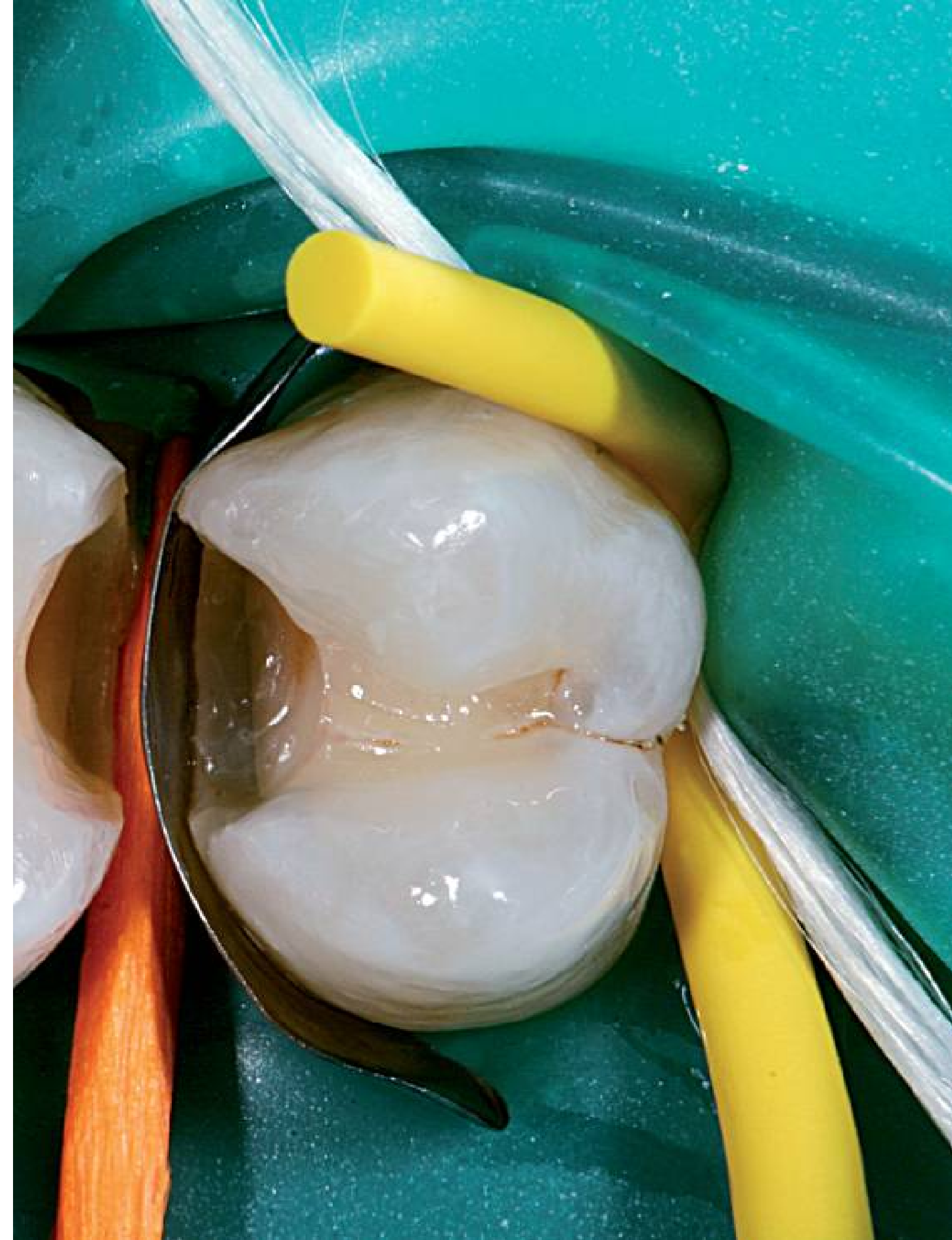An Editorial Forum for Dental Professionals





Preparation for adhesive composite filling.

*Image courtesy: Practice of Dr. Wolfgang Bolz, Prof. Dr. Hannes Wachtel,
Prof. Dr. Markus Hürzeler, Dr. Otto Zuhr, Dr. Wolf Richter, Munich, Germany*





*We thank Dr. Koschdon for kindly allowing us to take photographs in his practice.
Interior design: Jakob P. Koschdon, Frankfurt, Germany*



Margit Krause-Bonte

Dear Reader,

When making a decision during treatment, what you can see is a key criterion to your clinical evaluation. Time and time again during your work as a dentist, you almost certainly experience situations in which you would like to have more precise, magnified vision.

The possibilities offered by modern microscope systems have enormously extended the limits of visualization. Since its inception in 1953, the surgical microscope has become firmly established in numerous medical fields across a broad range of clinical applications. A large number of surgical procedures would now be totally inconceivable without the use of a microscope. Microscope magnification was an absolute must for medical progress to be made in fields such as cataract and retinal therapy, as well as ophthalmic, brain tumor and reconstructive vascular surgery.

In dentistry, the microscope has also redefined the concept of visualization. Particularly in the field of endodontics, the microscope is now generally recognized as an essential element in the dentist's daily armamentarium and part of the basic academic curriculum in endodontic programs worldwide. Beyond the endodontic practice, the role of the microscope has received increased attention in general dentistry to further enhance the quality of the dentist's work, obtain aesthetic outcomes and conserve long-term dental health for patients. In addition, the integrated or attachable camera and video equipment of modern microscope systems permits the dental professional to involve patients to a much greater extent in the treatment process and increase overall treatment compliance. A magnified microscopic image is worth more than a thousand words. It allows you to clearly explain the treatment and impressively demonstrate your skills. Last but not least, the dental microscope makes it possible for you to sit in an ergonomically correct, relaxed and upright position during therapy.

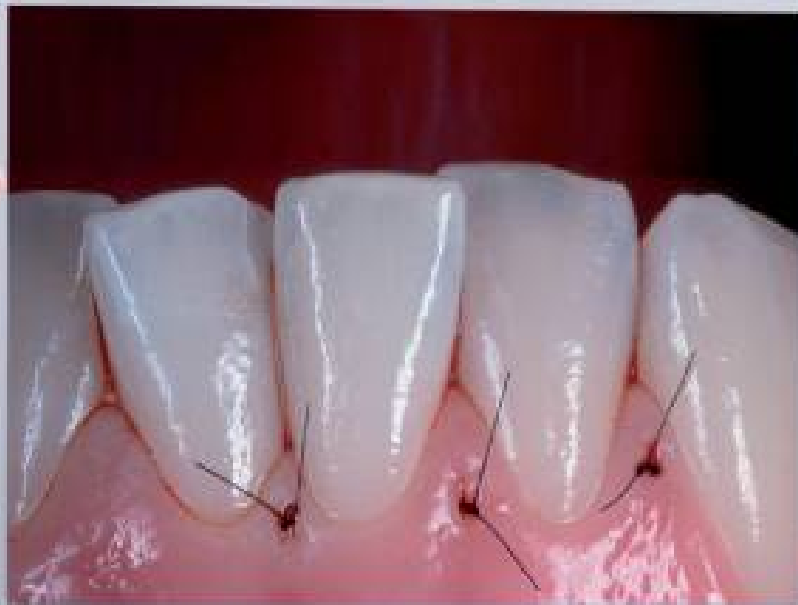In this publication we wish to give dental microscope users a platform to pass their valuable clinical experience and knowledge onto others. We hope you will find this collection of reports interesting, providing you with new dimensions of knowledge for your everyday work.

Enjoy!

Sincerely,

A handwritten signature in blue ink that reads "Margit Krause-Bonte". The script is fluid and cursive.

Margit Krause-Bonte
Director
Business Sector Dental and ENT Office



*Patient education ensures treatment compliance.
Image courtesy: Dr. Rino Burkhardt, Zurich, Switzerland*

5	Editorial	
8	Frequently Asked Questions about the Dental Microscope Hidde Doornbusch, DMD Kasper Veenstra, DMD	
11	The Advantages of Using the Dental Microscope in Restorative Dentistry – A Practically Oriented Report Wolfgang Gänslar, DMD	
16	The Dental Microscope: An Indispensable Tool in Endodontic Practice Thomas Clauder, DMD	
20	The Dental Microscope: Modern Techniques in Periodontology Give the Patient a New Smile Markus B. Hürzeler, DMD, PhD Sebastian von Mohrenschildt	
22	Use of the Dental Microscope in Plastic Periodontal Therapy – Evolution or Revolution? Rino Burkhardt, DMD	
26	How the Dental Microscope Offers Powerful Perspectives for Digital Visualization Philip Tan, BDSc, MSD	
29	Enhancing Ergonomics and Workflow in Microdentistry: OPMI® pico with MORA Interface Publication for the IDS 2005 by Assad F. Mora, DDS, MSD, FACP	

Frequently Asked Questions about the Dental Microscope

Hidde Doornbusch, DMD / Kasper Veenstra, DMD

Since gaining our first experience with the dental microscope in 1996, we have attended many courses and congresses on this topic – among them, at the Microscope Training Center directed by Dr. Syngcuk Kim at the University of Pennsylvania, Philadelphia, USA. Over time, we have gained a profound understanding of microscopes in dentistry which led us to start our own practical course on dental microscopy which has been running since 1998. During our courses we are confronted time and time again with many questions on microscopy. The following represents the most important questions, e.g., those where the answers epitomize the basics for understanding the benefits of a dental microscope.

What is the added value of a microscope for dentistry in general?

With a microscope, dental procedures can be performed more accurately and more reliably using variable and adjustable magnifications and shadow-free light due to a coaxial radiating light source.

In general, magnification can be set to between 4x and 24x, thereby expanding the diagnostic options due to better lighting and sight. For example, most fissure caries and microfractures cannot be seen with the naked eye. With the aid of a microscope it is even possible to view down to the apex of a straight root canal.

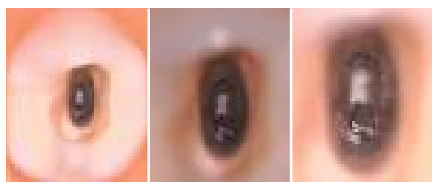


Fig. 1: Different magnification levels

Additionally, clinicians will experience an increase in their job satisfaction. Many procedures are simplified and accelerated greatly, as much better visibility is provided with the microscope. Treatment results become more predictable. For

example, the outline preparation and assessment for a crown preparation becomes much simpler. Making a cast impression is also no longer problematic. Moreover, working with a dental microscope improves ergonomics. The microscope allows for the best possible working posture. Neck and back injuries can be prevented. Existing injuries may, in some cases, disappear suddenly.

The dental microscope works according to the telescope principle, whereby the furthest point of view is at infinity. Therefore, the eyes do not accommodate and converge, which means that fatigue rarely occurs.

Furthermore, patients can be better counseled and educated. With a video camera attached to the dental microscope, the images can be recorded directly. This greatly simplifies the counseling of patients because, as we all agree, sometimes an image says more than a thousand words.

What is the added value of the dental microscope for endodontics?

During root canal treatment most procedures take place inside a tooth. Treatment is often performed with a basic knowledge of the dental pulp and x-ray findings. The dental microscope,

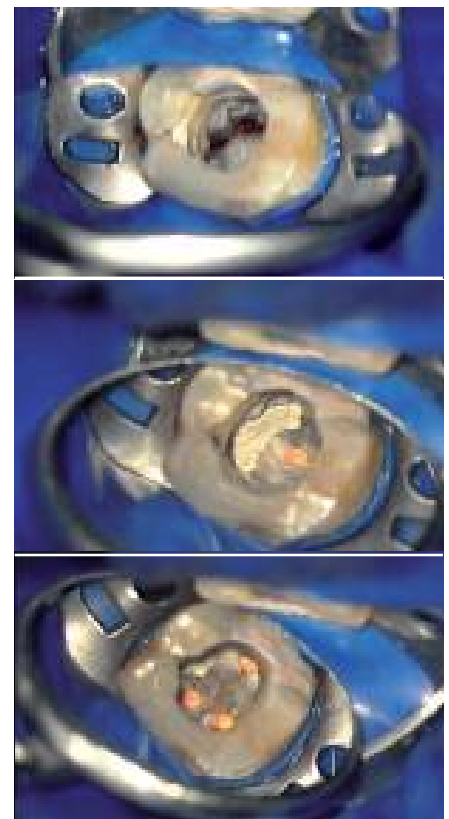

Fig. 2: Perforation sealed with mineral trioxide aggregate (MTA) during root canal treatment

however, displays a large part of the pulp chamber. The big advantage is that the dentist can now see what is being treated and where.

Enhanced visualization significantly simplifies work, especially for complicated treatments. In particular, this applies to the complete removal of the pulp roof, especially if it is partially attached to the pulp floor. Likewise, it is easier to locate canal entrances that are difficult to access and to display the links between the canals as well as perforations, bends, split or oval canals. It also enables the identification of fractures.

Root canal instruments that have broken off as well as old root canal filling material can also be removed more easily. The treatment of an open apex and the complete filling of canals are both simplified when utilizing the microscope - especially in cases with deep splits. This can occur regularly in upper and lower premolars.

The assessment of filing quality can be improved. For example, it can be seen clearly if a 0.6 hand file is worn down very quickly which can result in the complete loss of its filing capacity. Defects in rotary files can be traced at an early stage resulting in the likely prevention of a number of fractures.

Do you have to get use to operating a dental microscope?

Absolutely. At first, people are mainly

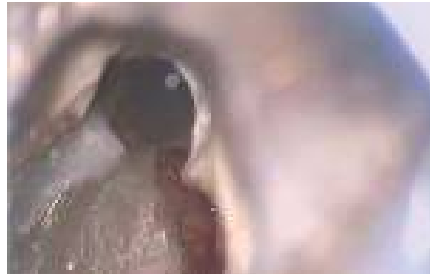

Fig. 3: Vital pulp in the 4th canal

surprised about the level of detail and the things that previously remained unseen. Treatment might be slightly slower in the beginning.

However, after initial training, the speed and efficiency of treatment improves, until the working pace almost resumes its previous speed. Eventually, almost all treatments can be performed more predictably and faster with a dental microscope.

Are special instruments required for working with a dental microscope?

Working with a dental microscope requires instruments designed to keep fingers from getting in the way – in other words, hand spreaders instead of finger spreaders, rotary files instead of hand files as well as microsurgery instruments for apex resections.

Drills with longer shanks are more convenient as it is easier to see down them.

What accessories does a dental microscope include?

With a dental microscope it is possible to record videos or take still images since it provides adaptable and integrated mounting options for video cameras as well as digital and SLR cameras. A printer can then be used to print images of the case and treatment situation.

A co-observation tube attached to the microscope housing, or a monitor connected to the dental microscope, allows the assistant to follow the procedures by viewing the magnified details directly through the microscope or on the monitor.

We have been using a microscope since 1996, when we began performing endodontic treatment. Shortly after, we started using a microscope during all our general procedures. Even though a practical training regimen is recommended at the beginning, you will see impressive results within just a few hours of practice with a dental microscope!

Image courtesy: Dr. Hidde Doornbusch and Dr. Kasper Veenstra, Hoogezand, The Netherlands

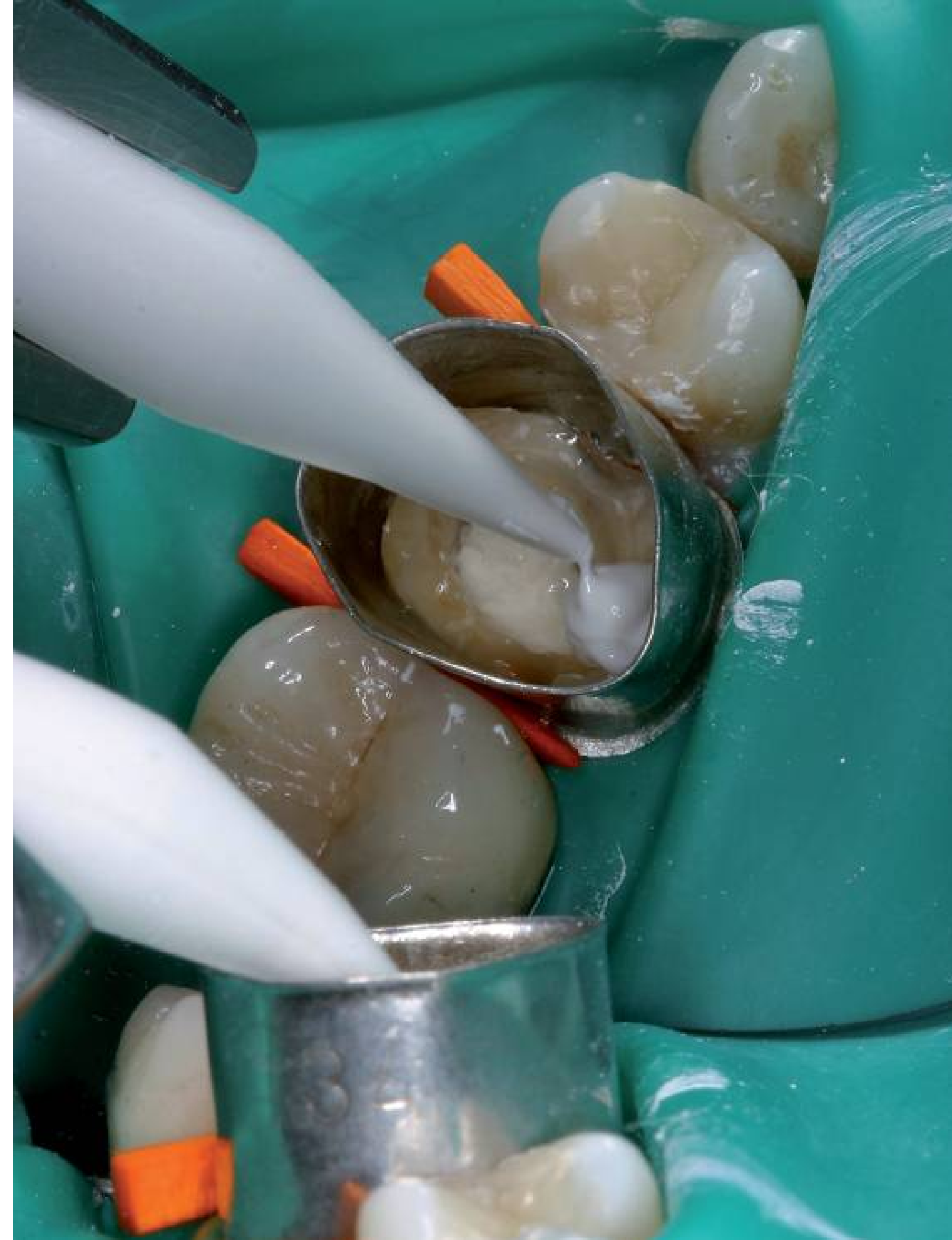


Dr. Hidde Doornbusch received his DMD degree from the University of Groningen, The Netherlands. He carried out research at the University Hospital Groningen and at the University of Groningen, Department of Oral Surgery. He was a general dental practitioner in Hoogezand, The Netherlands, with a part-time practice in endodontics. Dr. Doornbusch attended the Microscope Training Center at the University of Pennsylvania, USA. Since 1996, he used a microscope for all dental procedures in his general dental practice but had a special interest in endodontics. He invented a guidance system for safely preparing a root canal for a root post. Dr. Doornbusch was President of the European Society of Microdentistry (ESMD) and gave master classes for AMED. He published several papers regarding the dental microscope. Dr. Doornbusch unfortunately passed away in October 2007.



Dr. Kasper Veenstra received his DMD degree from the State University of Utrecht, The Netherlands. He practices dentistry at his general dental practice in Hoogezand, The Netherlands, and has used a dental microscope there since 1996. He attended the Microscope Training Center at the University of Pennsylvania, USA. Dr. Veenstra gives hands-on courses on the use of a dental microscope. He is a clinical instructor at the University of Groningen for endodontic students and gives master classes for AMED. He is member of the Executive Committee of ESMD and Chairman of the Foundation for Postgraduate Courses in the North of The Netherlands.

Dr. Veenstra can be reached at K_Veenstra@beterlichtenzicht.nl | www.beterlichtenzicht.nl



The Advantages of Using a Dental Microscope in Restorative Dentistry – A Practically Oriented Report

Wolfgang Gänslar, DMD

Restorative dentists have been using magnifying optical systems, such as medical loupes and dental microscopes, for a long time. They have become an integral part of daily treatment. In this article I would like to highlight my personal successes after over 10 years of active application in daily routine, and explain the benefits and technological opportunities of such a “perfect visual aid” with a practice-oriented description.

Over the past 15 years there have been a number of fundamental technical changes in restorative dentistry. Restorative dentistry nowadays is no longer simply restricted to primary prosthetics-oriented treatment of a patient by providing appropriate work made in the dental laboratory. For colleagues practicing restorative, holistic dentistry it is now possible to provide patients with both aesthetic and functional restorations from the periodontal and endodontic foundation onward, after undergoing further training in certain specific disciplines and investing in those areas. These special fields include all aspects of periodontology, a systematic adhesive bonding technique, high-quality root canal therapy, periodontal plastic surgery, implant dentistry, and ultimately, after a lengthy period of treatment, permanent, functional and aesthetic restoration techniques (Fig. 1).

The first American specialist endodontists began integrating the dental microscope into their routine activities back in the mid 1980s. European restorative dentists were made aware of the use of the microscope in endodontics by American endodontists at the beginning of the 1990s. In Germany in the mid 1990s, colleagues with a high sense of technical commitment, such as Schlee, Dieterich, Iglhaut, and myself, began in-

tegrating the current design of the dental microscope into their practice concepts.

Reasons for turning to a dental microscope

Further development of adhesive bonding techniques, plus an increasing desire over the past 10 years to preserve teeth, has resulted in endodontics becoming highly important in restorative dentistry. In addition to the adhesive stabilization of teeth subjected to endodontic therapy, it was the introduction of the dental microscope that significantly increased success rates in primary and revision endodontic therapy as well as retrograde, apical surgery (Fig. 2).

Due to the prevailing physical laws and weak, shady illumination of an endodontic or periodontal subgingival surgical site by the operator lamp, any outcome-oriented dentist reaches limits even with high-magnification loupes (up to approximately 5x magnification).

Recognition of the 4th canals existing in 98% of multi-root posterior teeth, the minutest lines of development and connection, a fractured foreign body, isthmuses, leakages, and ramifications in the deep root sections, is the domain of the dental microscope.

In this context the dental microscope

with xenon illumination is the technologically perfect instrument for working in and on teeth with precision, optimal illumination, and variable magnification levels.

First experience with a dental microscope – today’s standard

In 1996 I visited the ZEISS showrooms in Oberkochen, Germany. There, I decided in favor of a motorized dental microscope with an adjustable magnification level, xenon illumination, ceiling suspension, and technical features like a 180° tilting tube, dovetail mount as well as image and video documentation systems.

Like any new system that we integrate into our practice routine, working with the dental microscope slowed down procedures initially. Process sequences and instrument offering also had to be developed and the assistant trained to support dental microscope-based therapies.

If used on a daily basis, which is only feasible with a user-friendly dental microscope, the learning curve is very steep. Within six months the dental microscope became indispensable for complex endodontic and surgical interventions. During the following 10 years I began using the dental

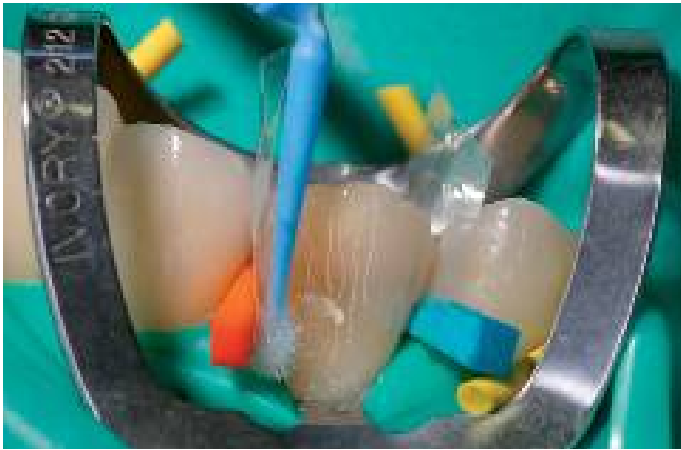

Fig. 1: Application of adhesive on enamel

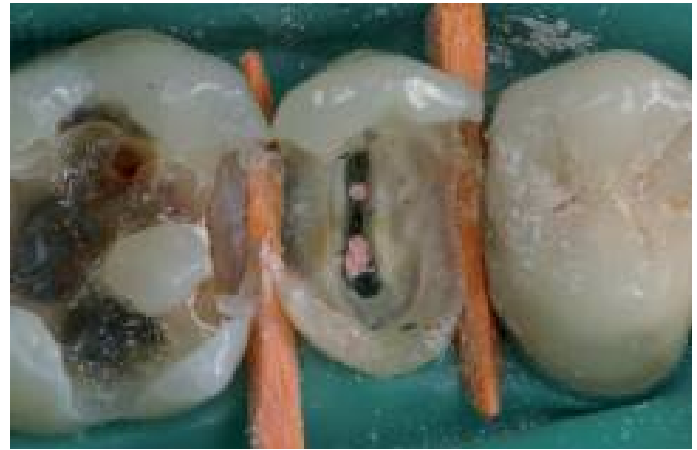

Fig. 2: Endodontic revision therapy

microscope as an integral part of my restorative therapies.

When we moved to new, more spacious premises and upgraded a treatment room that has an area of approximately 60 square meters and also serves as a seminar room for live operations, I switched to a new ZEISS dental microscope: the OPMI® PROergo system. This system was even more user-friendly than my proven ZEISS OPMI PROdent. The OPMI PROergo dental microscope allows optimal, ergonomic work even when treatment continues for several hours.

In the following section, I would like to describe in detail the advantages of using a dental microscope in restorative dentistry on a daily basis, which I now consider quite substantial.

Visualization of pathological findings for (new) patients – communication support

If the dental microscope features the appropriate video recording equipment, it is ideal for showing the (new) patient pathological findings vividly and visually. Together with a video documentation system such as the ZEISS MediLive® MindStream system, it is also possible to create a DVD for the patient due to undergo extensive and complex restoration work, and treatment sequences

can be recorded and archived.

In addition to visualization, these recordings can also be used to provide convincing evidence to insurance companies. These video recordings are not to be underestimated as a form of quality assurance as, when reviewed, they enable dentists to reexamine complex therapies.

Comfortable treatment and ergonomics due to technological advantages

Since, with a dental microscope, it is technically feasible to feed xenon light into the observer's beam path view at an angle of less than 4°, illumination of even filigree sections of the surgical field is perfect. In conjunction with motorized zooming very local detail can be recognized, especially in endodontics.

As far as I was concerned, motorized adjustment of the focal length was one of the key points in favor of OPMI PROergo because, as opposed to my former system OPMI PROdent with its fixed focal length, this is a major advantage for daily work ergonomics. During procedures, which can take up to 2 hours, the dentist not only sits very upright, which is good for the back, but can now also position the patient vertically at such a small angle that the shoulder girdle is as relaxed as possible and the arms have an

appropriate and relaxed grasping radius. Due to the 180° tiltable tube and the dovetail mount, the dentist always sits in a completely vertical posture and does not even have to tilt his head, which would have strained the neck muscles during lengthy sessions.

Conservative, adhesive restorations after systematic caries excavation

In cases with extensive carious defects and deep cavities, and where caries excavation is performed systematically and followed by adhesive management with built-up resin fillings, onlays placed at a later date may function properly for many years.

If caries is to be excavated close to the pulp, I like to use the dental microscope because, due to its shadow-free light in conjunction with rhodium-plated mirrors, it is excellent for distinguishing even the minutest of infected areas (Figs. 3, 4). The closer to the pulp the operator needs to work while removing caries, the more this type of optimal vision enables great care to be exercised.

Routine dental techniques – tooth extractions with complications

Which dentist has not experienced a seemingly simple extraction of a devitalized premolar that has undergone inadequate endodontic therapy, or an extraction of a

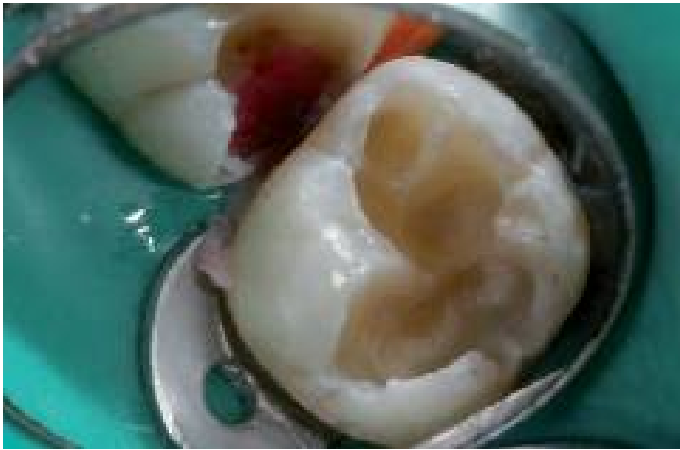

Fig. 3: Caries excavation close to the pulp

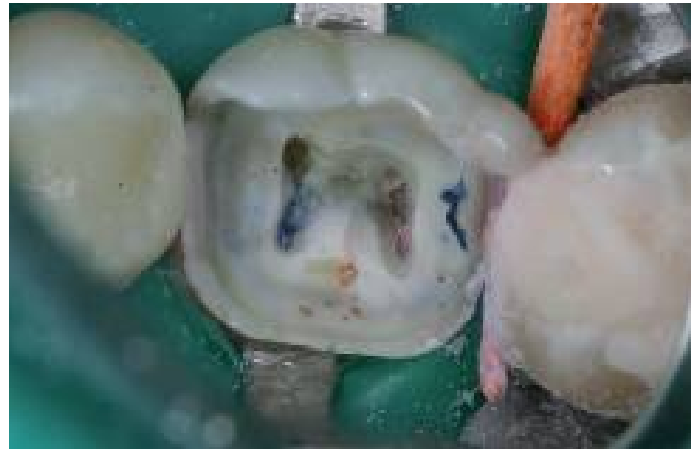

Fig. 4: Canal visualization after excavating caries from tooth 36

partially retained wisdom tooth that suddenly involved complications? The tooth fractures, individual fragments can only be removed with difficulty due to sclerosis of the individual roots with the bone, and vision is impaired by bleeding. Here, too, the dental microscope provides steady conditions due to its excellent illumination and adjustable magnification. The dentist can zoom down to the depth of the extraction alveolus and thus very precisely mobilize a stubborn root remnant if the assistant ensures minimal bleeding with the use of a special-purpose microaspirator. With microscope-assisted tooth extraction, the alveolar bone can also be preserved with a view to subsequent implantation.

Periodontal therapy in visually barely accessible (subgingival) root sections

In closed or open periodontitis therapy, based on the Full Mouth Therapy Concept, one often has the problem that the deep subgingival pockets or interdental recessions and furcations already affected by bone destruction are hardly accessible to the naked eye. Due to the optical benefits mentioned and the illumination of the surgical field, I like to use the dental microscope in these instances because it is possible to detect any clinging islands of biofilm and remove them precisely.

Orthograde and retrograde endodontics – the domain of the dental microscope

During the initial phase of my self-employment as a dentist, I was very dissatisfied with the quality of my endodontic therapies. In one particular case, (posterior) teeth that had undergone proper endodontic treatment caused the patient pain soon after the endodontic therapy. The patient was subsequently referred to an orthodontic surgeon, who worked conventionally without a dental microscope, for an apicoectomy. The patient's retrograde therapy was also only temporarily successful.

Due to the further endodontic training sessions I attended back in 1994/1995 with many American endodontists, among them Dr. Clifford Ruddle (Santa Barbara, California, USA) and Prof. Syngcuk Kim (University of Pennsylvania, Philadelphia, USA), I became aware that much higher success rates could be achieved in endodontics. At those presentations and courses I suddenly saw verification x-ray images showing 4 and 5 root canal systems which those endodontic professionals were able to localize by using a microscope.

As I explained in the introduction, it was just a small step toward purchasing the first ZEISS dental microscope of my own

and gaining my first experiences with this slightly different "visual aid". Now, after 10 years of extensive use of the dental microscope in all restorative disciplines, it has become an indispensable part of my (endodontic) routine (Fig. 5).

The long-term success rates in orthograde and retrograde endodontics have risen toward 100%, firstly due to the more conservative preparation philosophies and the thermoplastic filling technique, and secondly due to the use of dental microscopes. The shadow-free, bright xenon light enables the straight canal sections to be examined right down to the constriction.

Ledges, branches, fractured instruments, perforations, foreign bodies, and even isthmus-like branch lines can be localized and simultaneously treated with slender ultrasonic tips under optimal, magnifying vision. The localization of absent canals, pulp denticles, tooth-colored restorations in the pulp chamber, and removal of old, insufficient root canal fillings is much more reliable when using magnification systems such as dental microscopes or medical loupes.

If, despite a seemingly sound orthograde root canal filling, apical inflammation does occur in a few cases - usually where apical ramifications are inaccessible - a

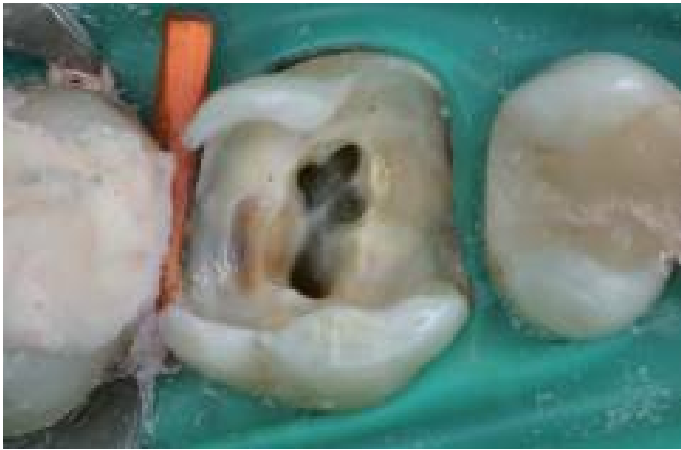

Fig. 5: Localization of the middle mesial canal 27

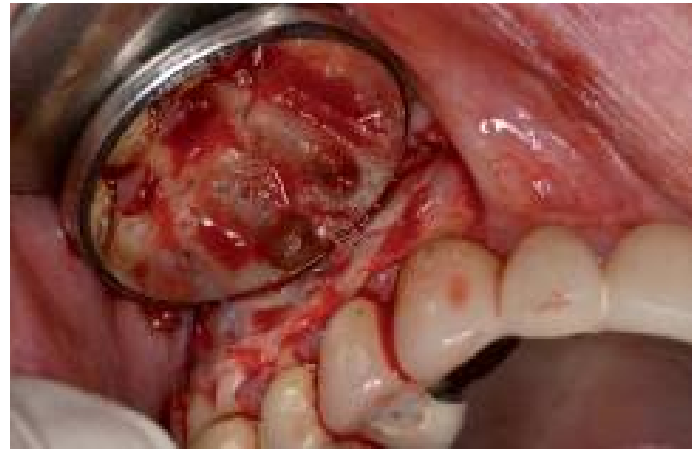

Fig. 6: Apical microsurgery on tooth 15

dental microscope is also a great help in apical microsurgery (Fig. 6). Again, the filigree apical portion of the root can be removed under optimal illumination and the leakage delta responsible for the inflammation prepared with ultrasonic tips and ligated with a suture.

Diagnosis of minute longitudinal fractures is often only possible at a magnification level exceeding 12x to 15x. Here too, the dental microscope provides useful diagnostic reliability.

Microsurgical techniques in periodontal plastic surgery and implant surgery

Application of microsurgical principles from vascular surgery to plastic dental surgery created a desire to use very fine suture material at a high level of magnification. Apart from the development of microsurgical instruments it was the medical loupe with a magnification of approximately 5x and the dental microscope with an even higher magnification that made it possible to see size 7.0 or 8.0 suture materials.

Incised sections of papilla must be adapted as precisely as possible, especially in the crucial, highly aesthetic, anterior gingival region. Here, a dental microscope allows excellent monitoring of suture use and ligation placement (Fig. 7).

Precise control of prosthetic preparations and impressions

In order to ensure precise preparation of a hard tooth structure, especially in the final phase of patient rehabilitation performed according to a treatment plan, it is essential to provide the dental technician with preparation margins that are as accurate as possible – irrespective of whether the restorations are to be made of gold or porcelain. I prepare the teeth to be restored using medical loupes before completing a final check or producing a preparatory finish under the dental microscope - it can be swung over the patient in a matter of seconds (Fig. 8). As part of the chain of precise quality assurance, I can also quickly check the impressions for accuracy under the dental microscope. When performing treatment with the dental microscope, over the years I have discovered that with an evolving level of training one can employ the dental microscope quickly and in many different ways, without slowing working procedures significantly more than when practicing using medical loupes.

The dental microscope as a high-quality marketing and positioning instrument

Routine work at a higher level of magnification encourages the dentist to maintain precision and accuracy, which represent integral parts of any high-quality,

restorative practice philosophy. In my personal opinion, this technological development which enables the dentist to see every detail and can open up a new world of dental treatment simply by employing a user-friendly, well-equipped microscope, should not be underestimated.

I think that everywhere in the world an increase in the number of dental practitioners has brought about a situation where we are all competing for the same patients. Additionally, patients today are well aware of their role as clients in the dental health service sector and have the technical facilities for obtaining information easily (e.g., the internet). The less social security systems contribute to high-quality treatment using state-of-the-art methods, the more critical and performance-oriented those patients will be who can still afford modern, high-quality dentistry. In comparison to dentists working conventionally yet adequately, any colleagues working under magnification using a medical loupe or dental microscope are in a position to handle highly complex treatments successfully and will therefore have an enormous advantage.

For me, the dental microscope has added quite considerable technical reliability to my dental treatment routines. A command of even seemingly very difficult endodontic therapies, in conjunction with an increase

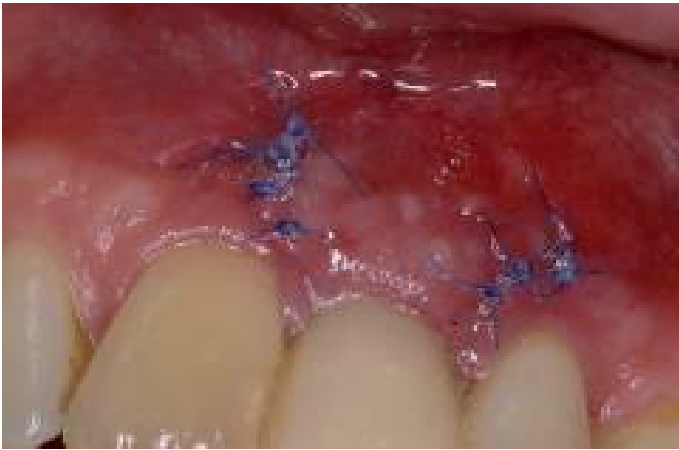

Fig. 7: Microsuture 5 days after implantation and augmentation

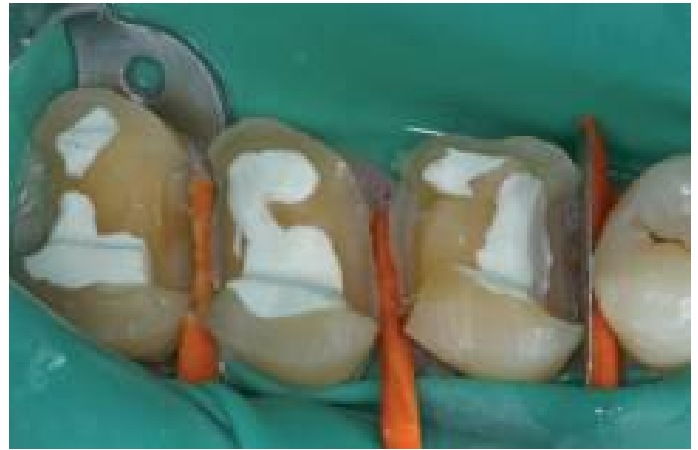

Fig. 8: Preparation of a quadrant for porcelain onlays

in experience and operating know-how, has meant that I am extremely confident when handling patients. A dental microscope in conjunction with the willingness to undergo further training and development in the specialized fields mentioned creates a wonderfully “unique selling proposition” in the competitive world of dentistry that is not easy to emulate.

For the past 10 years I have witnessed how delighted patients are who have undergone complex endodontic therapy with the aid of a dental microscope along with all other special endodontic instruments which combine to form wonderful advertising media. The difference from previous visits to the dental office is extremely obvious to the patient during treatment.

Conclusion – the advantages of using a dental microscope

In writing this practice and experience report my intention was to point out some advantages of the dental microscope that I have experienced during my career as a dentist employing microscopy. For me the acquisition of a dental microscope was one of the two crucial factors in my development to become a specialized restorative dentist. The microscope, in conjunction with further technological developments and an increase in experience, is bound to lead to specialization that will continue to enjoy a high degree of protection against emulation in the competitive world of dentistry.

One advantage of using the dental

microscope that should not be underestimated, especially in the physically and psychologically highly strenuous dental profession, is a healthy, namely upright, working posture. Due to its superior technological features a convenient-to-use microscope can provide the dentist with considerable quality of life and good health. To put it crudely, the microscope can “hump up” for us as we sit in a highly ergonomic, upright position keeping the spine relaxed.

In my opinion, the dental microscope, with all its advantages, is now absolutely indispensable in any quality and outcome-oriented dental practice philosophy.

Image courtesy: Dr. Wolfgang Gänsler, Illertissen, Germany



Dr. Wolfgang Gänsler earned his DMD degree from the University of Ulm, Germany, and has continued highly intensive postgraduate training in all dental fields since then. He maintains his private practice in Illertissen, Germany, specializing in restorative dentistry with periodontal, endodontic, and functional pretreatment as well as full-mouth rehabilitation in centric mandibular relation. Since 1999, he has increased microendodontic orthograde and retrograde referral work. He has been working with a dental microscope in his practice since 1996. Dr. Gänsler holds live demonstration courses on endodontics and functioning as well as aesthetic composites. He also lectures about practice concepts and rubber dams as well as digital photography and much more.

Dr. Gänsler can be reached at Dr.Gaensler-Fortbildungen@t-online.de | www.praxis-dr-gaensler.de

The Dental Microscope: An Indispensable Tool in Endodontic Practice

Thomas Clauder, DMD

High-quality endodontic therapy is the basis for long-term function and biologic success, ensuring that patients remain free of pain. State-of-the-art equipment and thorough clinical know-how are vitally important to reach this goal. Today, the world's leading practicing dentists and researchers are largely in agreement that in endodontics the dental microscope has pushed the limits of treatment potential a long way towards enhancing long-term patient outcomes.

Nowadays, teeth that require endodontic therapy can provide a basis for many aesthetically demanding prosthetic restorations. Routine endodontic practice, however, confronts the practitioner with an increasing number of challenges (Fig. 1).

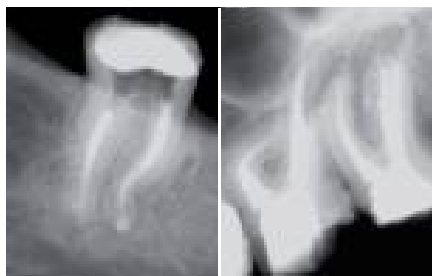

Fig. 1: X-ray images of S-shaped and crooked root canals

For example, anatomical variations are not as rare or exotic as is frequently assumed and can in themselves form the basis for disease. Walter Hess described the complex anatomy of root canals in great detail as early as 1917.⁴ Subsequent anatomical studies have since been published in various countries and a broad range of populations. Many of these important structures cannot be readily detected or treated with traditional endodontic treatment methods. Failures in non-surgical and surgical endodontic therapy were frequent, and they still are. This is reflected in daily

dental practice and cross-sectional epidemiological studies. The discrepancy between possible successful prognosis and reality is quite substantial.

The introduction of the dental microscope and the associated ability to inspect the root canals – both orthograde and retrograde – have fundamentally changed our understanding of dental morphology and its complexity.

However, following the first publications there was no widespread acceptance of microscopic techniques among dentists, until the beginning of the 1990s. Well-known specialists such as Prof. Syngcuk Kim (University of Pennsylvania, Philadelphia, USA) and Dr. Gary Carr (San Diego, USA) facilitated the establishment and widespread use of microscopic techniques. Prof. Kim's motto "You can only treat what you can see!" has made dentists all over the world enthusiastic about microscopic treatment. In 1998, the American Dental Association instituted microscope proficiency as obligatory for all endodontic specialist programs in the USA.

As the use of dental microscopes increased worldwide, new instruments became established, the utilization of which greatly facilitates a considerable amount of work under the microscope. For a restorative dentist or endodontic specialist, the dental microscope offers

a large number of benefits:

1. Better visualization.

Due to the magnification, and clear coaxial illumination of the working field, it is possible to address unique or specialized treatment situations more efficiently and with greater precision.

2. Improved treatment quality.

Microscopic techniques are superior to traditional treatment concepts, as has been proven by various studies.^{1,7,8,10}

3. Ideal treatment ergonomics.

Appropriate working posture and ergonomics play a key role in maintaining the dentist's own health and personal well-being. For some colleagues, this is the main criterion for daily use in their practice (Fig. 2).

4. "Fun factor" in the practice.

Clinicians that utilize a dental microscope will find they have more enjoyment during procedures due to the ideal working conditions and the predictable treatment outcomes. They will be more motivated as treatment is experienced more intensely and visualization is improved considerably. Dentists, assisted by illumination, magnification, and special instruments, will also gradually experience a greater level of personal satisfaction. This is driven by their ability to recognize much greater detail, visualize many more root

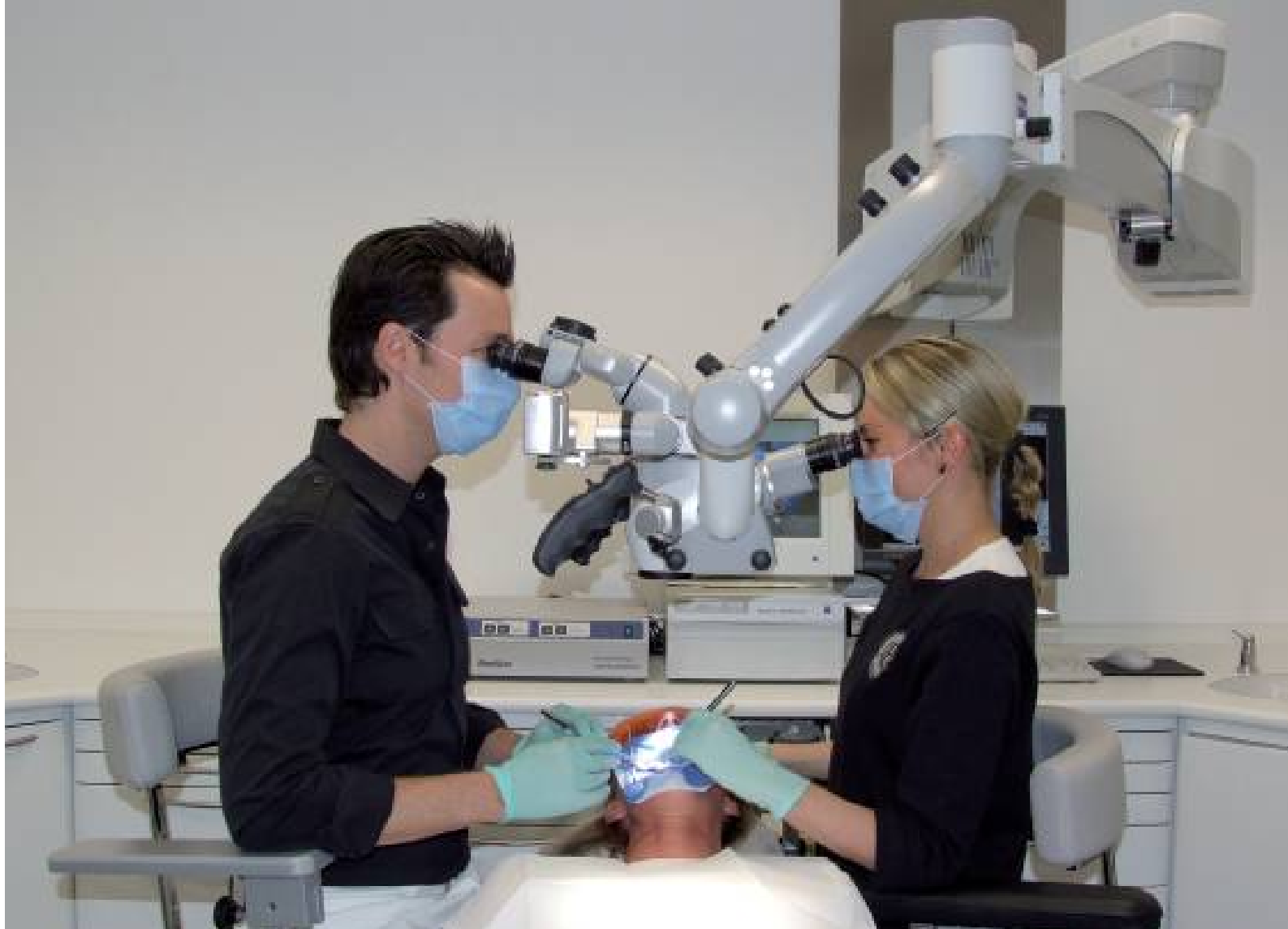

Fig. 2: Dr. Thomas Clauder and Dr. Caroline Neumann working with OPMI® PROergo equipped with a co-observation tube

canals and anomalies, treat them successfully, and ultimately achieve more therapy successes, particularly those with spectacular results. The dentist can explain this to the patient and, through enthusiasm and fascination, enable him or her to participate in this positive effect.

In all areas, from exposure of the access cavity and preparation to three-dimensional obturation and postendodontic management, the microscope provides major advantages over working without appropriate magnification. As a result, the use of the microscope can be expressly recommended for the following specific indications and special aspects:

1. Diagnosis.

Microfractures and longitudinal fractures are often overlooked clinically and represent a cause of pain that is difficult to diagnose (Figs. 3, 4). Visualization

under the dental microscope is the basis for further treatment planning.

2. Canals/canal systems that are difficult to localize.

If the radiographic image is examined more closely, there are often signs of unusual root and/or canal shapes like those caused by changes in the course of canal anatomy or root surface. Interruptions in the canal shape are almost always a certain indication of canal system splitting. An off-center exposure or three dimensional image can provide further valuable information. Three-rooted premolars, for example, are encountered in six percent of all first maxillary premolars (Figs. 5, 6).² However, anatomical variations also include other complex structures like C-shaped canals. In the case of second mandibular molars, they account for approximately 7.6%. However, in Asian

populations such as in Koreans they can reach up to 31.3% (Figs. 7, 8).^{5,9,12} Treatment of this anatomical variation can be highly complex. Without a doubt, the second mesiobuccal canal in maxillary molars, which is often difficult to localize and prepare, is the reason why the failure rate is highest in first maxillary molars (Fig. 9). Depending on the literature source, the frequency of the fourth canal is determined to be between 52% and 95.2% in vitro and between 16% and 78% in vivo.³ Virtually all studies point to distinct advantages in the localization of second mesiobuccal canals when using a dental microscope.

3. Obliterations and calcifications.

These signs occur to a greater or lesser extent in 50% of all teeth, impairing instrumentation considerably or essentially preventing treatment of the canal system (Fig. 10).

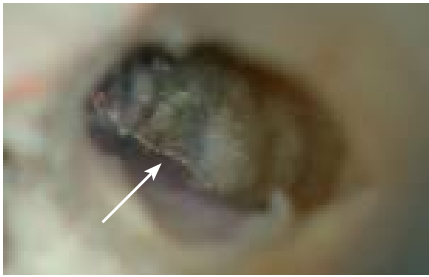

Fig. 3: Microfracture diagnosed during orthograde root canal treatment

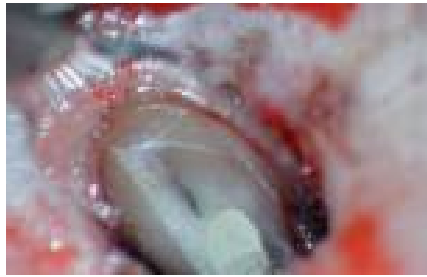

Fig. 4: Microfracture diagnosed during microsurgical endodontic treatment

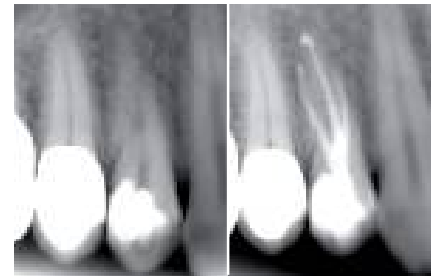

Fig. 5: X-ray images of a three-rooted premolar (pre- and postoperative)

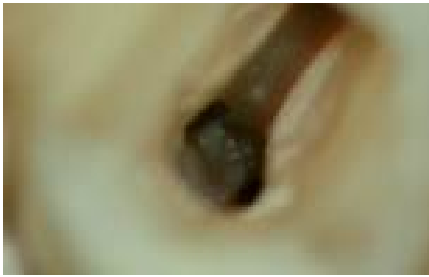

Fig. 6: Buccal separation of a three-rooted premolar

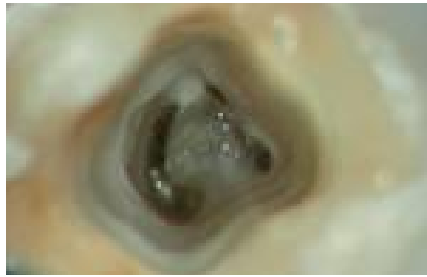

Fig. 7: Excavation of a C-shaped root canal

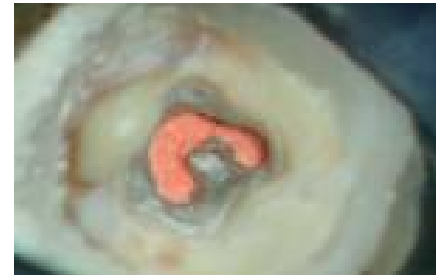

Fig. 8: Obturation of a C-shaped root canal

4. Denticles.

This specific form of calcification is also encountered very frequently. Denticles can be found even on the molars of young patients in 19.7% of cases.⁶ They can block the canal entrance or even obstruct further instrumentation (Fig. 11).

5. Open apex.

Modern apexification therapies call for special treatment techniques and materials, the manipulation of which is facilitated significantly under a dental microscope (Figs. 12-14).

6. Perforation repair and removal of fractured instruments.

Treatment of these iatrogenic problems

and treatment prognosis chiefly involve visualization of the problem so the microscope certainly plays a major role in this context. If, for example, the fragment can be removed without any major loss of tooth structure, the prognosis for preservation of the tooth is quite good (Figs. 15, 16).

7. Microsurgical apicoectomy.

Modern techniques involve: microsurgical flap design and suture techniques, atraumatic procedures during resection, management of the bone structures, minimally invasive retrograde cavity preparation and retrograde filling of the canal system and all its branches. Modern microsurgical concepts were published

by Prof. Kim in the 1990s. They provide not only an atraumatic procedure and fewer complications for patients, but also a much better prognosis than traditional procedures (Fig. 17). While conventional apicoectomies can expect prognoses with a success rate of around 60%, the prognosis for a microsurgical procedure is significantly better.

A very convincing study concerning the benefits of microsurgical procedures was reported by Rubinstein and Kim in 1999.^{7,8} While the short-term investigation confirmed healing in 96.8% of cases⁷, the follow-up after 5-7 years also attains an amazingly good healing success rate of 91.5%.⁸ This is well

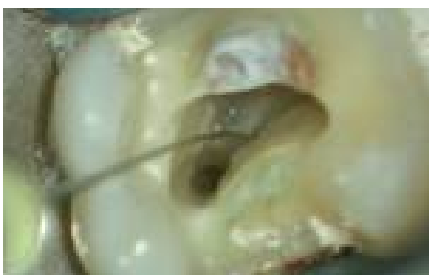


Fig. 9: Localization of the second mesio-buccal canal (MB II) of an upper first molar

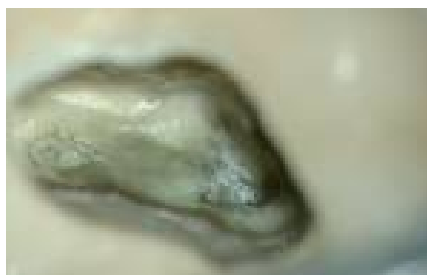


Fig. 10: Obliterated canal orifices impair instrumentation or even prevent root canal treatment

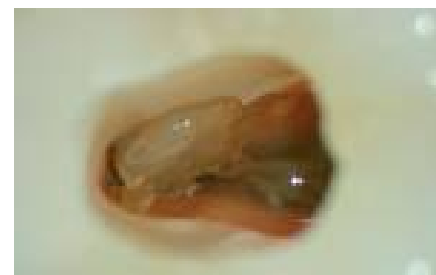

Fig. 11: Denticles may block the canal entrance

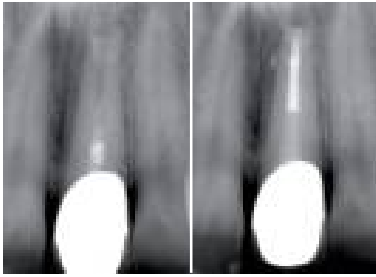


Fig. 12: X-ray images of the treatment of an open apex

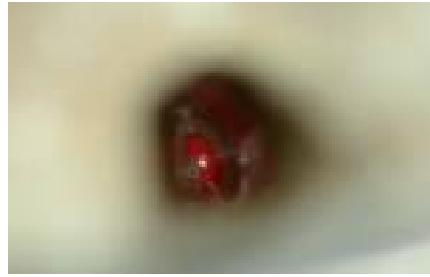

Fig. 13: Localization of the root canal end




Fig. 14: Creation of a barrier across the open apex, before obturation

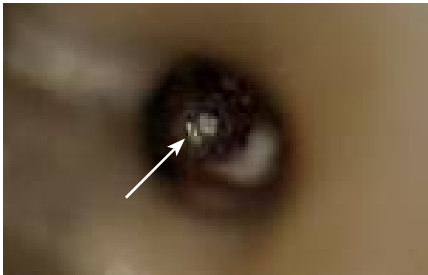


Fig. 15: Visualization of a fractured instrument is essential for retrieval

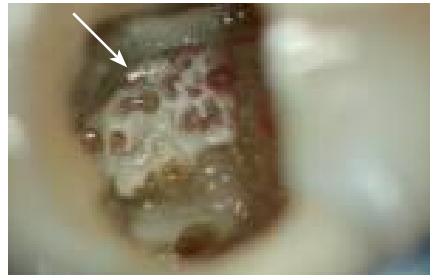

Fig. 16: Cleaned out perforation site and visible bone in the furcation

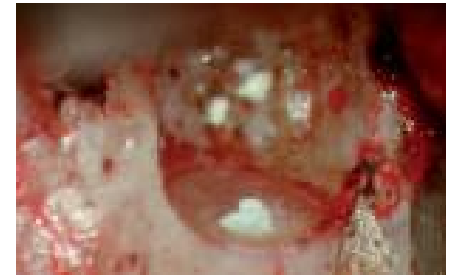


Fig. 17: Microsurgical retro-preparation and retrofill with mineral trioxide aggregate (MTA)

beyond the success rates of conventional apicoectomy procedures. Another study points to an even greater discrepancy of 44.2% for the traditional method and 91.1% for microsurgical techniques.¹¹

The dental microscope not only offers many useful applications in the treatment of root canals and throughout the entire field of dentistry, but also improves the overall treatment quality. It encourages dentists to review and perfect their own treatment concepts resulting in a positive impact on the entire practice structure.

Image courtesy: Dr. Thomas Clauder, Hamburg, Germany

References:

- Baldassari-Cruz L. A., Lilly J. P., Rivera E. M. (1998): Effectiveness of mesiolingual canal location with and without the use of the microscope. *J Endod* 1998; 24: 287 (abstract OR 63)
- Carns E. J., Skidmore A. E. (1973): Configurations and deviations of root canals of maxillary first premolars. *Oral Surg Oral Med Oral Pathol* 1973; 36: 880-886
- Görduyus M. Ö., Görduyus M., Friedman S. (2001): Operating microscope improves negotiation of second mesiobuccal canals in maxillary molars. *J Endod* 2001; 27: 683-686
- Hess W. (1917): Zur Anatomie der Wurzelkanäle des menschlichen Gebisses mit Berücksichtigung der feineren Verzweigungen am Foramen apicale. *Schweiz Vierteljahrsschr Zahnheilk* 1917; 27: 1-34
- Jafarzadeh H., Wu Y.-N. (2007): The C-shaped Root Canal Configuration: A Review. *J Endod* 2007; 33(5): 517-523
- Ranjitkar S., Taylor J. A., Townsend G. C. (2002): A radiographic assessment of the prevalence of pulp stones in Australians. *Aust Dent J* 47, 36-40
- Rubinstein R. A., Kim S. (1999): Short-term observation of the results of endodontic surgery with the use of a surgical operating microscope and Super-EBA as root-end filling material. *J Endod* 1999; 25: 43-48
- Rubinstein R. A., Kim S. (2002): Long-term follow-up of cases considered healed one year after apical microsurgery. *J Endod* 2002; 28: 378-383
- Seo M. S., Park D. S. (2004): C-shaped root canals of mandibular second molars in a Korean population: clinical observation and in vitro analysis. *Int Endod J* 2004; 37: 139-144
- Stropko J. J. (1999): Canal morphology of maxillary molars: clinical observations of canal configurations. *J Endod* 1999; 25: 446-450
- Tsesis I., Rosen E., Schwartz-Arad D., Fuss Z. (2006): Retrospective Evaluation of Surgical Endodontic Treatment: Traditional versus Modern Technique. *J Endod* 2006; 32(5): 412-416
- Weine F. S. (1998): The C-shaped mandibular second molar: Incidence and other considerations. *J Endod* 1998; 24: 372-375



Dr. Thomas Clauder is a graduate of the University of Hamburg, Germany. He has been working in a joint dental office in Hamburg since 1997 and has used a dental microscope since that time. After completing the International Program and obtaining his certification as a specialist from the University of Pennsylvania, USA, Department of Endodontics, he devoted his attention solely to endodontics and endodontic microsurgery. Dr. Clauder is a Certified Member of the European Society of Endodontology (ESE) and member of the American Association of Endodontists (AAE). He is also a charter member and former Vice President of the German Endodontics Association (DGEndo). Dr. Clauder can be reached at Thomas.Clauder@praxis-clauder.de | www.praxis-clauder.de

The Dental Microscope: Modern Techniques in Periodontology Give the Patient a New Smile

Markus B. Hürzeler, DMD, PhD / Sebastian von Mohrenschildt

Optical magnification has broadened the horizons of dentistry in general, and periodontology in particular. It has established microsurgical techniques for periodontal procedures by magnifying even minute anatomical structures, leading to enhanced mucogingival aesthetic outcomes by minimizing scarring and decreasing healing time.

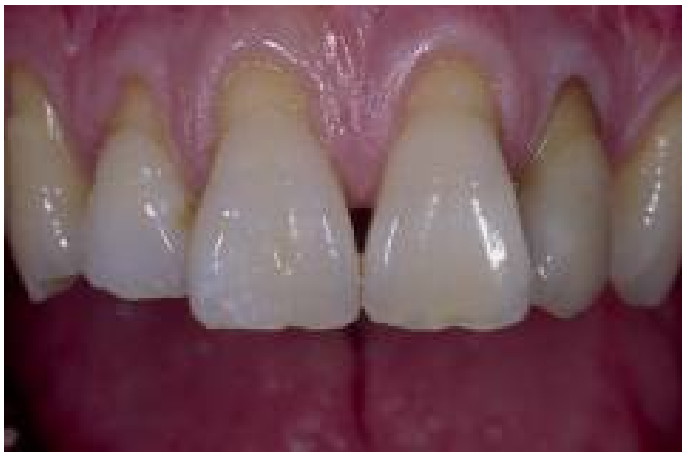

Fig. 1: Before Surgery

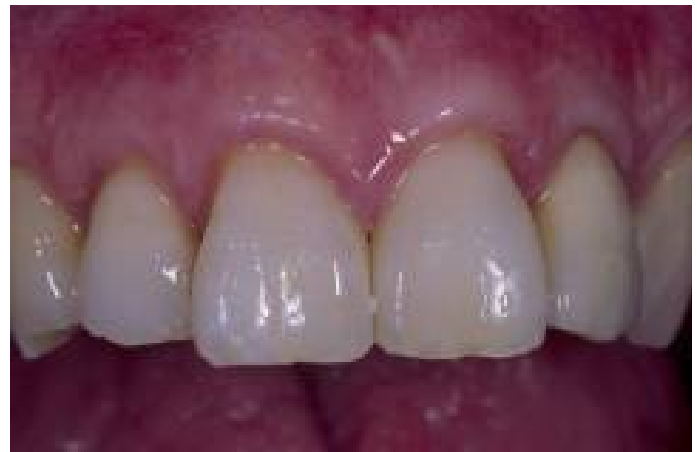

Fig. 2: After Surgery

Fifty years ago, the term mucogingival surgery was introduced and applied to surgical procedures that amended the relationship between gingiva and alveolar mucosa.⁵ Nowadays, mucogingival surgery has evolved from traditional pocket therapy into a plastic surgery method that includes periodontal, peri-implant and mucosal concerns (e.g., buccal root recessions, volumetric defects, unaesthetic or asymmetric gingiva) whether they are caused by anatomic, developmental, or traumatic deformation. Successful mucogingival invasion depends upon the selection of an atraumatic surgical approach, which is limited by surgeon skill and cognition of the human eye.

In the field of periodontology, an increased demand for mucogingival aesthetics has required the optimization of periodontal procedures such as periodontal microsurgery. Generally speaking, the term microsurgery

applies to surgical procedures performed with the aid of magnification systems like medical loupes or dental microscopes, adapted instruments and suture material.

The dental microscope, as a highly sophisticated system of lenses, allows binocular viewing at magnification of approximately 4x to 24x. The optical extension of the light beams, due to the system of lenses and prisms, effects accommodation of the eyes to virtual infinity so that no eye convergence is necessary and the demand on the eye muscle is minimal. The magnification recommended for surgeons ranges from 2.5x to 20x.^{1,12} In periodontal surgery, magnification of 4x to 5x for medical loupes and 10x to 20x for the dental microscope appears to be ideal. The dental microscope guarantees an ergonomic working posture, optimal, coaxial lighting of the operation region and quite freely selectable magnification levels. Recent develop-

ments in dental microscopes have also enabled direct viewing of oral operation sites. In many surgical specialties, such as neurosurgery, urology, plastic and eye surgery, treatment outcomes were significantly improved by applying minimally invasive techniques.^{7,11} Studies covering wound healing of extraoral operation sites have demonstrated that epithelization of a wound closed microsurgically was completed within 24 hours: minimal tissue trauma caused by a microsurgical incision and suture technique with primary wound closure results in reduced cell necrosis and, consequently, faster healing than with a macrosurgical approach.¹⁷ The use and advantages of the dental microscope have been extensively discussed in endodontic literature.^{3,18} The benefits of microsurgical approaches in periodontal therapy have also been described.^{2,4,13,14,15,16} As they are relatively frequent therapies in periodontology, root coverage and soft tissue augmen-

tation are fundamental to daily practice. Root coverage with free connective tissue grafts has a high rate of clinical success,^{8,9,10} whereas microsurgical techniques heal even more rapidly with minimal scarring, and therefore, enhance the aesthetic outcome. With proper lighting and visualization of the operation area, mucosal flaps can be prepared in equal thickness under a dental microscope without the risk of perforating the flap basis or the mucogingival junction. This is particularly important with double-split mucosal flaps, which traditionally place the highest demands on the surgeon. Closure of surgical wounds in a layer-by-layer fashion is indicated with all periodontal procedures where passive, tension-free wound closure is fundamental for wound healing and a successful functional and aesthetic outcome.⁶ Everyday periodontal surgery shows that healing and regeneration results are seriously compromised when the flap cannot be kept completely closed. Moreover, abundant fat parts at the connective tissue graft can be removed under complete control beneath a dental microscope, and the connective tissue can be trimmed with ease and precision to the necessary size, which favors rapid vascularization.

Periodontal microsurgery not only improves the results of free-connective tissue grafts with the split-flap technique, it is similarly advantageous to periodontal diagnosis and therapy. Magnification of the structures and favorable lighting improve the recognition of subgingival elements. Judgment of pocket tissue facilitates optimal flap adaptation and enables passive primary wound closure to be achieved. These techniques, therefore, decrease the duration of the healing period, the time required for resorption of the connective tissue graft, scarring, as well as patient pain and discomfort.

Image courtesy: Practice of Dr. Wolfgang Bolz, Prof. Dr. Hannes Wachtel, Prof. Dr. Markus Hürzeler, Dr. Otto Zuhr, Dr. Wolf Richter, Munich, Germany

References:

1. Apotheker H., Jako G. J. (1981): A microscope for use in dentistry. *J Microsurg* 1981; 3(1): 7-10
2. Burhardt R., Hürzeler M. B. (2000): Utilization of the surgical microscope for advanced plastic periodontal surgery. *Pract Periodont Aesthet Dent* 2000; 12: 171-180
3. Carr G. B. (1994): *Surgical endodontics*. In: Cohen S, Burns R C, eds. *Pathways of the pulp*. St Louis, MO: Mosby: 531
4. Cortellini P., Tonetti M. S. (2001): Microsurgical approach to periodontal regeneration. Initial evaluation in a case cohort. *J Periodontol* 2001; 72: 559-569

5. Friedman N. (1957): *Mucogingival surgery*. *Texas Dent J* 1957; 75: 358-362
6. Hürzeler M. B., Weng D. (1999): *Functional and esthetic outcome enhancement of periodontal surgery by application of plastic surgery principles*. *Int J Periodontics Restorative Dent* 1999; 19(1): 36-43
7. Komatsu S., Tamai S. (1968): *Successful replantation of a completely cut-off thumb*. *Plast Reconstr Surg* 1968; 42: 374-386
8. Langer B., Langer L. (1985): *Subepithelial connective tissue graft technique for root coverage*. *J Periodontol* 1985; 56(12): 715-720
9. Nelson S. W. (1987): *The subpedicle connective tissue graft. A bilaminar reconstructive procedure for coverage of denuded root surfaces*. *J Periodontol* 1987; 58(2): 95-102
10. Raetzke P. B. (1985): *Covering localized areas of root exposed employing the "envelope" technique*. *J Periodontol* 1985; 56(7): 397-402
11. Serafin D. (1980): *Microsurgery: past, present and future*. *Plast Reconstr Surg* 1980; 66: 781-785
12. Shanelec D. A. (1992): *Optical principles of loupes*. *CDAJ* 1992; 20(11): 25-32
13. Shanelec D. A., Tibbetts L. S. (1994): *Periodontal microsurgery*. *Periodontal Insights* 1994; 1: 4-7
14. Shanelec D. A., Tibbetts L. S. (1996): *A perspective on the future of periodontal microsurgery*. *Periodontol* 2000, 1996; 11: 58-64
15. Tibbetts L. S., Shanelec D. A. (1994): *An overview of periodontal microsurgery*. *Curr Opin Periodontol* 1994; 2: 187-193
16. Tibbetts L. S., Shanelec D. A. (1996): *Current status of periodontal microsurgery*. *Curr Opin Periodontol* 1996; 3: 118-125
17. Van Hattam A., James J. (1979): *A model for the study of epithelial migration in wound healing*. *Virchows Arch B Cell Pathol Incl Mol Pathol* 1979; 30: 221-230
18. Velvart P. (1997): *The operating microscope in root tip resection. I. The resection*. *Schweiz Monatsschr Zahnmed* 1997; 107: 506-516



Prof. Markus B. Hürzeler received his DMD degree from the University of Zurich, Switzerland, and his PhD from the Albert-Ludwig-University in Freiburg, Germany. Prof. Hürzeler practices periodontics, prosthodontics and implant dentistry in Munich, Germany, and is a Clinical Associate Professor at the Albert-Ludwig-University of Freiburg, Department of Operative Dentistry and Periodontology. He is also a Clinical Associate Professor at the University of Texas in Houston, USA, Department of Stomatology. He has been working with a dental microscope since 2003. Prof. Hürzeler lectures extensively on a national and international level and is the author of a number of publications and books. He has a certificate in prosthodontics from the German Society of Dental Prosthodontics and Material Sciences (DGZPW) and in periodontics from the German Society for Periodontology (DGP).

Prof. Dr. Markus Hürzeler can be reached at Markus@huerzeler.biz | www.z-z-m.de



Sebastian von Mohrenschildt graduated from the Freie Universität in Berlin, Germany. Since 2005 he has been practicing periodontics, prosthodontics and implant dentistry with the dental microscope in Munich, Germany. From 2005 to 2007 he participated in the postgraduate program at the "Zentrum für Zahnheilkunde" and now works in a dental practice specialized in aesthetic dentistry in Munich.

Dr. von Mohrenschildt can be reached at Sebastian.vonMohrenschildt@ipi-muc.de | www.z-z-m.de

Use of the Dental Microscope in Plastic Periodontal Therapy – Evolution or Revolution?

Rino Burkhardt, DMD

Since the 1980s, root coverage, increase of keratinized tissue around implants, augmentation of alveolar defects, and delocalization of the gingival line are among the surgical methods that have been introduced and modified within the field of mucogingival surgery (Figs. 1-3). Utilizing these procedures, the majority of periodontal concerns can be resolved successfully and predictably. However, the key to aesthetic and functional success as well as predictability is the selection of a minimally traumatic approach which not only depends on the surgeon's dexterity, but also on the perception of the human eye. Therefore, the use of magnification systems is essential to appropriately performing microsurgical techniques. It is the aim of this article to describe the technical components and benefits of the microsurgical technique applied in periodontal surgery.

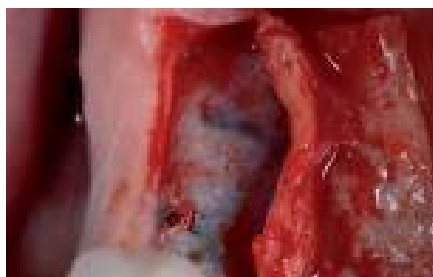


Fig. 1: Removal of a Gore-Tex membrane, combined with a double-split flap to increase the width of the masticatory mucosa

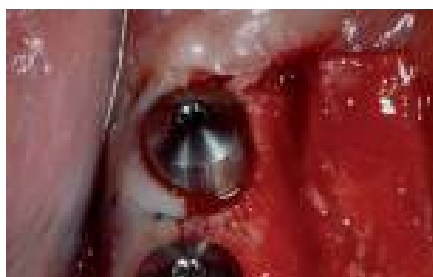


Fig. 2: Abutments placed, connective tissue flap sutured in place

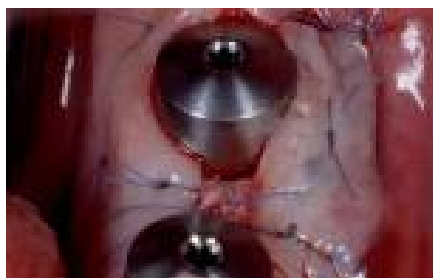


Fig. 3: Completed clinical procedure without denuded bone surfaces

Microsurgery in general is not an independent discipline, but merely a technique which can be applied in different surgical specialties. It is based on the fact that the human hand, when trained appropriately, is capable of performing more precise movements than the naked eye is able to control.

The advantages of the microsurgical technique have long been recognized in other surgical specialties and revolutionized the results in, for example, casualty and replantation surgery, as well as neuro and eye surgery. The entirely positive results of microsurgically modified interventions have led to today's clinical applications in dental treatment, seen first in endodontics.

The treatment results have been analyzed statistically since the introduction of microendodontic techniques and published in prospective studies. Within one year of apical surgery performed with a microscope, 96.8% of the cases were considered healed. A re-evaluation, 5 to 7 years after the first postoperative year, still yielded a success rate of 91.5%, measured by clinical and radiographic parameters.⁵ The corresponding percentage of healed cases, treated without a surgical microscope, yielded a success rate of only 44.1%.⁴

The first publications in periodontal

surgery were limited to case reports, based on subjective statements made by patients or the observations of the attending dental surgeons. Today, however, the benefits of microsurgical techniques are confirmed by scientific studies with a high level of evidence.

Technical aspect: Vision

Optimal vision is a strict necessity in periodontal surgery. Visualization of intricate detail is enhanced by increasing the image size of the object. Image size can be increased in two ways: first, by moving closer to the objects, and second, by visual magnification. Utilizing the former, the ability of the eyes' lenses to accommodate becomes important and has a relevant influence on the visual capacity.

As one ages, the ability to focus at closer distances is compromised because the lens of the eye loses its flexibility. Presbyopia affects all middle-aged people and becomes especially noticeable when the nearest point at which the eye can focus accurately exceeds the ideal working distance. This is why an older individual reading without glasses must hold the reading matter farther from the eyes to see the print. Increasing the distance enables the person to see the words but, on the other hand, the longer working distance means the written text appears smaller.

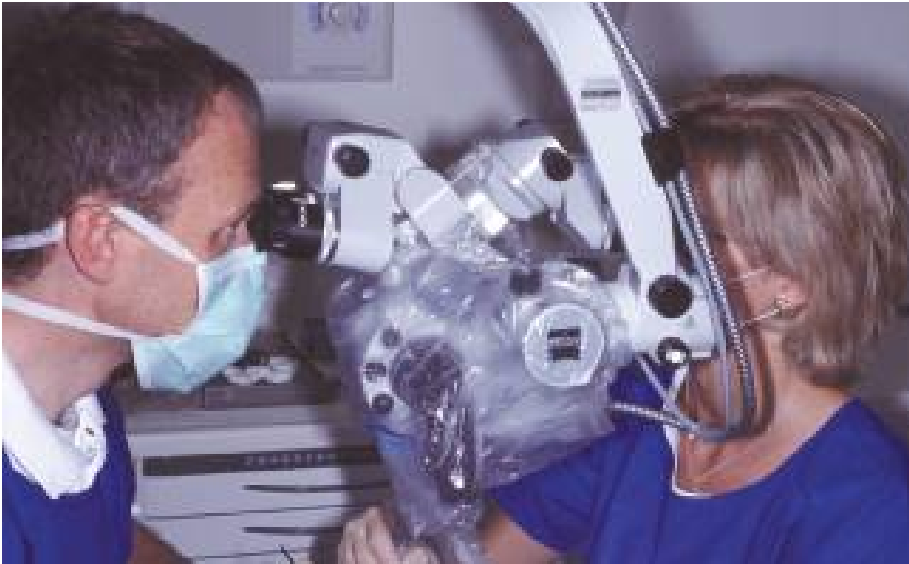

Fig. 4: Ergonomic posture for surgeon and assistant

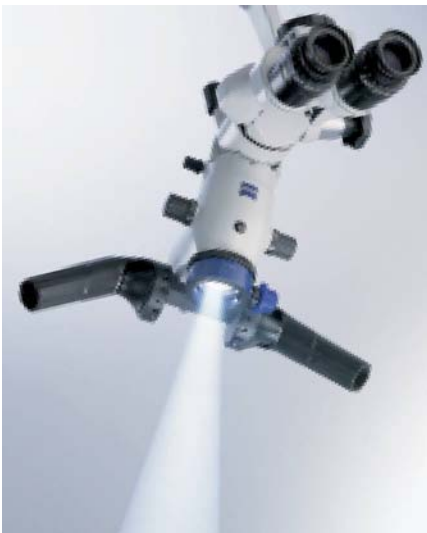

Fig. 5: The MORA Interface for OPMI® pico allows the operator to remain in an upright viewing position regardless of the angle of the microscope

The use of a dental microscope in the periodontal practice overcomes all these effects, provides the surgeon with a freely selectable magnification level, and additionally guarantees the ideal lighting conditions important for optimal visual acuity. While working with a microscope, in contrast to loupes, the light beams strike the retinas of the observer parallel so that no eye convergence is necessary thus placing only minimal demands on the lateral rectus muscles. Additionally, the dentist's head is placed in the center

of its balance point over the spine and stabilized against gravity. All these factors greatly improve postural ergonomics and avoid the multitude of back, neck, shoulder and eye problems that dentists frequently suffer (Fig. 4).

The microscope – consisting of numerous optical components, a lighting unit and a mounting system – is either attached to the wall, the ceiling or a floor stand.

During a surgical intervention, the surgeon uses both hands to perform the treatment procedure. For that reason a stepless, motor-driven magnification changer, operated by a foot pedal, seems to be more ergonomic.

Conversely, if the magnification needs frequent changes, it can be accomplished faster with the manual changer. In order to visualize lingual or palatal sites that are difficult to access, the microscope must have sufficient maneuverability. Recent technical developments have further enabled direct viewing of oral operation aspects (Fig. 5).

Instruments

Proper instrumentation is fundamental for a microsurgical intervention. Various manufacturers have complete sets of microsurgical instruments that are generally conceived for vascular and nerve surgery and are, therefore, inappropriate

for use in plastic periodontal surgery. An ideal basic set of instruments for plastic periodontal surgery consists of a micro-needle holder, micro-scissors, micro-forceps, small elevators and a variety of surgical blades. The precision with which the instruments are manufactured varies greatly. For example, the configuration of the needle holder jaw has a considerable influence on how firmly it grips the needle. Serrated inserts are the best at preventing the needle from twisting or rotating between the needle holder jaws. This benefit must be weighed against the potential harm the serrations may cause to the suture material. Smooth jaws cause no demonstrable damage to 6-0 monofilament nylon sutures, whereas serrated needle holder jaws markedly reduce the suture breaking strength. Additionally, the sharp outer edges of the needle holder jaws must be rounded to avoid breakage of delicate suture materials. When the needle holder jaws are closed, no light must pass through their tips. Locks aid in rotating the instrument handles in a controlled manner and without exerting pressure.

In order to prevent damage, microinstruments should be stored in a sterile container or tray. The tips of the instruments must not touch each other during sterilization procedures or transportation. The practice staff should be thoroughly instructed about the cleaning and maintenance of such instruments, as cleaning microinstruments in a thermodisinfector without fixing them in place may cause irreparable damage to their tips.

Suture material

The suture material and its application technique are essential considerations in microsurgery. Wound closure is a key prerequisite for healing following surgical interventions and most important for avoiding complications. However, penetrating the soft tissue with a needle causes additional trauma and the presence of foreign materials in a wound may significantly increase the susceptibility to infection. Hence, it's obvious that needle and thread characteristics also influence the wound healing and surgical outcome.

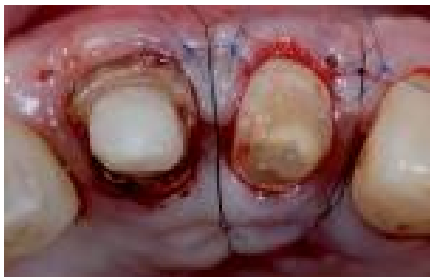

Fig. 6: Primary wound closure after papilla base incision

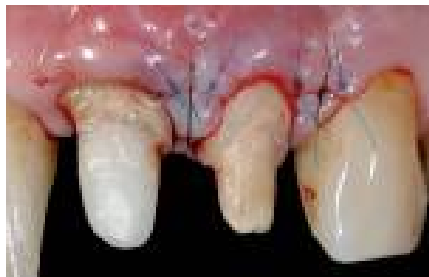

Fig. 7: Primary closure achieved with a microsurgically modified papilla suture

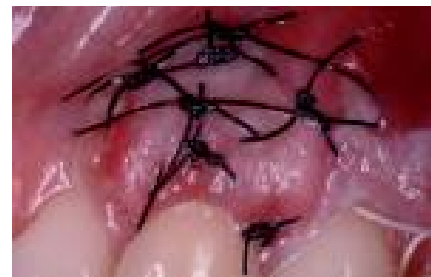


Fig. 8: Macroscopically treated recession, 7 days after intervention

Histological examinations confirmed the inflammatory tissue reactions with a distinct infiltrate. If a resorbable suture is left in situ for more than two weeks after wound closure, an acute inflammatory reaction will result. This is an indication that the sutures must be removed at the earliest biologically acceptable moment in time and that adverse quality, resorbable suture materials must be avoided in the bacteria-loaded oral cavity. Additionally, it was shown that bacterial migration into the tissues along the thread increases with higher diameter suture materials which, in turn, means that the selection of smaller diameter thread reduces the trauma and improves tissue healing. Polyfilament threads exhibit higher capillarity than monofilament threads and, in addition, facilitate bacterial migration. Bacteria can penetrate into the inner compartment of the thread which impairs the immunological response of the host. This is one more reason for favoring thin, monofilament, non-resorbable suture threads in periodontal surgery.

Clinical indications

At present, the degree to which the level of magnification influences the result of the operation can only be speculated. In the available literature, the magnification recommended for surgical interventions ranges from 2.5x to 20x.^{1,6} In periodontal surgery, a magnification range of 6x to 8x seems appropriate for clinical examinations or surgical interventions where an entire quadrant must be in the field of vision. As the depth of field decreases with increasing magnification, the maximum magnification for a surgical

intervention is limited to about 12x to 15x when dealing with a localized problem such as covering a single soft tissue recession or interdental wound closure after guided tissue regeneration of an infrabony defect (Figs. 6, 7).

Opponents of periodontal microsurgery often mention the adverse effect of the prolonged duration of the intervention while working with microscopes. It has been shown in studies from the 1980s that the incidence and severity of complications and pain following periodontal surgery correlate well with the duration of the surgical procedure. It may be speculated that an extended operation time may compensate for the beneficial treatment effect of minimally invasive techniques. However, recent surgical studies did not support such a hypothesis. Quite the contrary, in a recently published cohort study comparing loupe users, microscope users and dentists working without magnification, the microscope users fulfilled the specified tasks with the highest level of precision and incurred the least complaints about ergonomic posture problems.

Most periodontal surgical interventions require primary wound closure using a previously raised flap. This can be accomplished by choosing an appropriate suture material and technique. A recent experiment aimed to evaluate the influence of suture strengths and needle characteristics on the tearing behavior of mucosal tissue samples. The tearing-tension diagrams were plotted for 3-0, 5-0, 6-0 and 7-0 monofilament threads. The results demonstrated clearly that

dynamic tearing to breakage could occur either at the tissue level or within the threads. While the 3-0 sutures almost exclusively led to tissue breakage, within the 7-0 group the threads broke before tissues were torn. This in turn means that the clinician can influence the amount of trauma by selecting thinner suture material which, on the other hand, requires magnification.

In many instances, appropriate previous training facilitates cooperation with the assistant and automates instrument handling during surgery so that the operating team can fully concentrate on the surgical procedure.

From a subjective point of view as well as on the basis of the available literature data, there is no contraindication for the use of magnification in periodontal surgery.

Scientific data

Most of the periodontal studies from the 1990s, which evaluate the beneficial effects of the application of the microsurgical technique, are case reports. However, since the beginning of this century, more and more scientific data support the improved results with a high level of evidence when applying minimally invasive techniques.

One prospective cohort study clearly demonstrated the improved treatment outcomes with the use of microsurgical techniques when compared with macroscopically performed flap surgery.³ The use of a dental microscope was associated with a very high ability to obtain and maintain primary wound closure

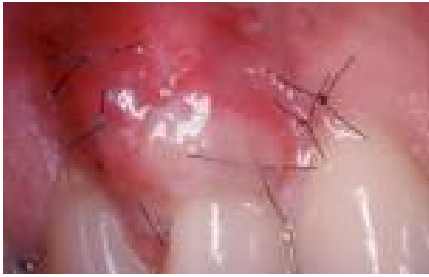

Fig. 9: Microsurgically treated recession, 7 days after intervention

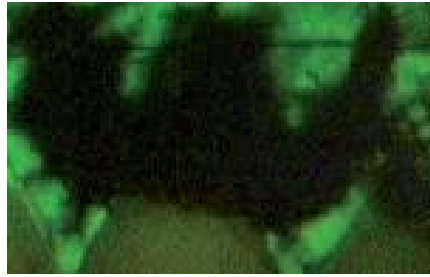

Fig. 10: Angiographic evaluation of a macro-surgical site, 7 days after the intervention

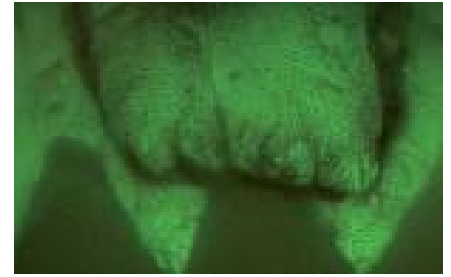


Fig. 11: Angiographic evaluation of a micro-surgical site, 7 days after the intervention

of the interdental tissues over barrier membranes in regeneration procedures. This could be accomplished by optimal visualization of the intricate details, resulting in enhanced clinical handling of the soft tissues.

Another study compared the short and long-term results after recession coverage procedures in a prospective, randomized clinical trial.² In a split-mouth design, buccal root recessions on upper canines were either covered microsurgically or macrosurgically. The angiographic evaluation performed immediately after the surgical interventions, and again after three, and finally, after seven days documented the statistically significant improved vascularization of the microsurgically treated sites compared with the conventional approach (Figs. 8-11). The clinical follow-up during the first postoperative year confirmed the beneficial effect of the microsurgical approach which contributed with a 10% improvement in mean recession coverage.

These results are corroborated by recent studies comparing microsurgical and macrosurgical approaches in periodontal therapy.

Conclusions

In periodontal practice, we often have to deal with problems where the naturally given visual capacity reaches its limits. Therefore, the tasks can only be partially fulfilled or at a lower level of precision and the use of magnification becomes mandatory to improve the quality of work. A substantial number of periodontists have already adopted the use of magnification provided by loupes and dental microscopes in their practices and recognize its value.

However, despite the entirely positive results in prospective studies, the dental microscope continues to experience slow acceptance in periodontal surgery. An anticipated extended learning curve and the financial investment may keep many practitioners from a trial session or attending a microsurgical course.

Although the microsurgical approach in periodontal plastic surgery is documented as being superior to conventional methods, evolution continues to take time!

Image courtesy: Figs. 1-4 and Figs. 6-11: Dr. Rino Burkhardt, Zurich, Switzerland

References:

1. Apotheker H., Jako G. J. (1981): A microscope for use in dentistry. *J Microsurg* 1981; 3(1): 7-10.
2. Burkhardt R., Lang N. P. (2005): Coverage of localized gingival recessions: comparison of micro- and macrosurgical techniques. *J Clin Periodontol* 2005; 32: 287-293.
3. Cortellini P., Tonetti M. S. (2001): Microsurgical approach to periodontal regeneration. Initial evaluation in a case cohort. *J Periodontol* 2001; 72: 559-569.
4. Friedman A., Lustmann J., Shaharabany V. (1991): Treatment results of apical surgery in premolar and molar teeth. *Journal of Endodontics* 17: 30-33.
5. Rubinstein R. A., Kim S. (1999): Short-term observation of the results of endodontic surgery with the use of a surgical operation microscope and Super EBA as root-end filling material. *J Endod* 1991; 25: 43-48.
6. Shanelec D. A. (1992): Optical principles of loupes. *CDAJ* 1992; 20(11): 25-32.



Dr. Rino Burkhardt earned his DMD from the University of Zurich, Switzerland, and he holds a Master of Advanced Studies degree in Periodontology. He maintains his private practice limited to periodontology and implantology in Zurich where he has been using a dental microscope since 1992. Dr. Burkhardt attended the Microsurgery Training Institute in Santa Barbara, California, USA. He acts as a clinical instructor in the Department of Periodontology, at the University of Berne, Switzerland. His publications, lectures and courses cover selected topics on his specialty. These include hard and soft tissue management within the scope of implant restorations, aesthetic aspects from the point of view of the periodontist and the relationship between the prosthetic restoration and periodontal tissues. Dr. Burkhardt won the 2006 research prize from the European Federation of Periodontology. He is an active member of the European Academy of Esthetic Dentistry (EAED), the European Association of Osseointegration (EAO), the Swiss Society for Periodontology (SSP) and the Swiss Society of Implantology (SGI).
Dr. Burkhardt can be reached at Rino.Burkhardt@bluewin.ch

How the Dental Microscope Offers Powerful Perspectives for Digital Visualization

Philip Tan, BSc, MSD

Appropriate procedural documentation is an important component of the dental patient's education and treatment record. It allows for an unbiased representation of a patient's presenting condition, the progress of treatment and the eventual outcome. In particular, digital visualization technology in combination with the dental microscope can be used as a powerful documentation tool for patients' records, legal documentation as well as the education of the dental profession.

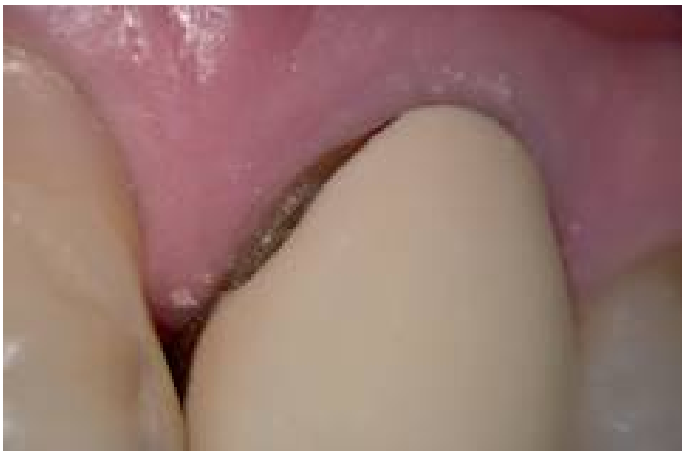

Fig. 1: Defective crown margin

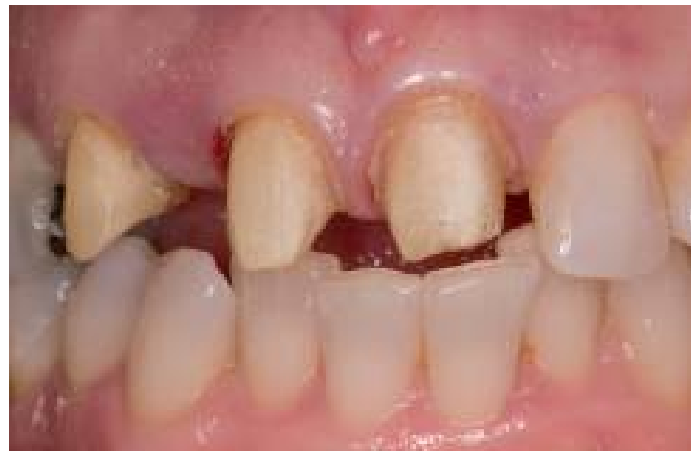

Fig. 2: Inadequately fixed partial denture

Current digital visualization technology has advanced significantly in recent years. The captured images and videos can be stored in any number of data formats (such as RAW, JPEG, TIFF or DNG for digital images as well as AVI and different MPG formats for digital video recordings) and transferred around the world in a matter of minutes. Despite these advances, in a busy private practice, appropriate photo documentation can still be a time consuming and inconvenient process. It is nearly the same with digital video documentation. Intra-oral video cameras designed specifically for dentistry have made the process somewhat simpler, but it still involves a break in the procedure. Video sequences can suffer from poor resolution, slow frame rates, distorted images and unrealistic color rendition.

However, the introduction of the dental microscope offers an integrated, efficient solution for daily practice and documentation. The benefits the microscope brings to the practice of dentistry extend beyond improved ergonomics and enhanced object visualization. When coupled with the appropriate capture devices, the microscope becomes an instrument for the projection and recording of clinical findings in a streamlined and efficient manner. Moreover, it allows the recording of precisely what the dentist sees. A remote control, foot switch or computer timer can be used to record the images without the need for significant intervention from the dentist or interruption of treatment progress.

In my private prosthodontic practice, I use the OPMI® PROergo dental

microscope from Carl Zeiss together with an attached external 3 CCD video camera and an SLR digital camera. The use of both of the devices together fulfills my needs for image documentation by allowing digital still and video capture. The video camera is set up to record all the time with the output directed to the ZEISS MediLive® MindStream image and video documentation system. MediLive MindStream displays the procedure on its integrated monitor and also records all the procedure steps for later review. The editing capability allows for fast and convenient video manipulation during the patient visit enabling the presentation of pertinent treatment points to the patient. An additional benefit is that the assistant is able to indirectly view the surgical field to keep abreast of the procedure's progress as well as anticipate the next

step. Additionally, the exported video recordings allow producing of a polished presentation for professional display and student education.

A particular instance where a video stream was useful for patient education was a situation where an individual presented with a fixed partial denture (FPD) that had debonded at one abutment. Using a recorded video stream, I was able to show the patient how much the FPD was moving and why it was necessary to remove it and investigate the cause of the movement. As it turned out there

I typically use digital still images to document a patient's condition when a higher resolution image is required. For example, Figure 1 shows clear evidence of a defective crown margin. The patient had initially been skeptical about the diagnosis, but when shown the evidence it was a simple matter to conclude that intervention was necessary.

It is also a simple matter to document pre-existing tooth preparations underneath an inadequate fixed partial denture (Fig. 2) compared with more appropriate tooth preparations (Fig. 3).

of a microscope's halogen light source is adequate for most documentation purposes. However, a xenon light source provides a much brighter light allowing the use of lower ISO settings and higher shutter speeds. A dual iris diaphragm may also be introduced to increase the depth of field in particular instances.

The dental microscope has many benefits, and when integrated with documentation devices it offers an unparalleled opportunity to document patient care in an efficient manner and unique perspective.

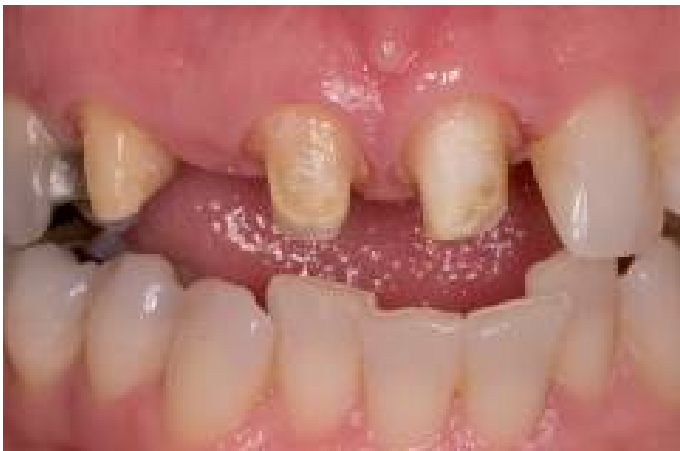

Fig. 3: Appropriately fixed partial denture

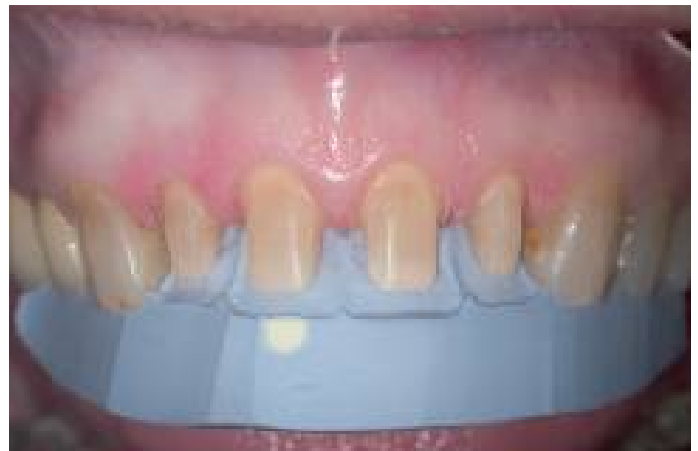

Fig. 4: Tooth preparation for all-ceramic crowns


was a fracture in the core of the abutment tooth. The tooth had to be restored with a cast post/core and new FPD. Had the situation been left for a period of time, the progress of dentine caries may have rendered the tooth unrestorable and necessitated extraction and a more complicated prosthetic solution.

Figure 4 was captured as part of a series of photographs used in a continuing education course to demonstrate appropriate tooth preparation for all-ceramic crowns.

A key element in digital visualization and documentation is illumination. The use

of a microscope's halogen light source is adequate for most documentation purposes. However, a xenon light source provides a much brighter light allowing the use of lower ISO settings and higher shutter speeds. A dual iris diaphragm may also be introduced to increase the depth of field in particular instances.

Image courtesy: Dr. Philip Tan, Melbourne, VIC, Australia



Dr. Philip L. B. Tan received his MSD degree from the University of Iowa, USA, and his Bachelor degree from the University of Melbourne, Victoria, Australia. Dr. Tan was Visiting Assistant Professor at the Department of Family Dentistry at the University of Iowa. He won first prize in the 2004 Stanley D. Tylman Research Competition. The award honor outstanding research supported by grants from the American Academy of Fixed Prosthodontics. Dr. Tan's project focused on fracture resistance of endodontically treated incisors with varying ferrule heights and configurations. Since 2006, he has worked with a dental microscope in his private prosthodontic practice in Melbourne, Australia. Dr. Tan also gives presentations and lectures on the dental microscope in prosthodontics and restorative dentistry.

Dr. Tan can be reached at ptanau@yahoo.com.au



75 • • • • • 7

Carl
f 170

ZEISS

1.6
2.5

Enhancing Ergonomics and Workflow in Microdentistry: OPMI® pico with MORA Interface

Publication for the IDS 2005 by Assad F. Mora, DDS, MSD, FACP

The operating microscope has been an essential instrument in my private practice since 1992. Once I became “hooked” on the visual advantage provided by the microscope in my daily practice, I became more aware of the ergonomic shortcomings that occasionally made the microscope a difficult instrument to use.

In 1998, Friedman et al. reported that the microscope is unusable in certain areas of the mouth. In an effort to make the microscope more user-friendly, one must first understand how the traditional microscope is positioned for use in dentistry. The traditional microscope is positioned to facilitate the seating of the operator between the 9 and 11 o'clock positions, the same position used by right-handed dentists who don't use a microscope in their practice. The 9–10 o'clock seating positions allow for securing the smallest distance possible between the operator and the patient's mouth, while allowing for a direct visual access into the oral cavity when the patient is reclined into a supine position. Unfortunately, the access opening to the mouth is not located in the horizontal plane for most dental procedures. Instead, the opening of the mouth has a downward inclination towards the chin. With that in mind, the operator must now rotate the microscope laterally along the sagittal axis, which causes the eyepieces to be on an inclined plane. This in turn forces the operator to assume an inclined neck position toward the right shoulder to accommodate the placement of the eyes on the eyepieces of the microscope. Working with an inclined neck posture is usually coupled with the over extension of the left arm (assuming a right handed operator) to facilitate the holding of the mouth mirror for use, either as a mirror, or as a retractor. This combination of muscle tension leads to fatigue, pain and musculoskeletal disorders, and possibly disability. For the microscope user to be comfortable when

using the microscope, it requires a posture where muscle tension is minimized and equalized between the left and the right sides of the body and the arms. The ideal microscope position that can be conducive to assuming such posture must allow the operator to be seated in the 12 o'clock position and allow for adequate extension of the microscope between the objective lens and the eyepieces that is at least equal to the distance between the top of the head of the patient to the patient's mouth, to prevent the operator from bending forward to reach the eyepieces and cause strain on the lower back. The MORA interface was developed in response to the challenges listed above.

Definition:

The “MORA Interface” is a Mechanical Optical Rotating Assembly that connects at a right angle the binocular tube to the body of the operating microscope to make it capable of a limited independent rotation around the horizontal axis of the binocular tube.

Description:

The suspension system is directly attached to the MORA Interface instead of attaching directly to the body of the microscope. The body of the microscope is then attached vertically to the port of the Interface facing the floor, while the inclinable binocular tube is attached horizontally to the port facing the operator. It is designed to maintain the eyepieces level with the horizon during tilting or panning of the microscope body from side to side, to a maximum of $\pm 25^\circ$.



Microscope Ergonomics:

The use of the microscope does not change the basic ergonomic principles associated with gaining visual and working access familiar to non-microscope operators. In that, gaining visual access as well as working access to the operating field are totally dependent on the limitations imposed by the posture of the operator. While working with the microscope forces the operator to sit upright, as dictated by the selected focal length of the objective lens and the added dimension between the objective lens and the eyepieces, it makes microscope positioning limited by the operator's ability to keep his/her eyes on the eyepieces within an imaginary envelope of postural extensions that can accommodate various microscope positions relative to the operator's eyes.

Postural Problems with Working under Microscope Magnification:

1. Restricted and posture-dependent access: Gaining visual access to the operating field with a microscope is a process totally dependent on the operator's postural limits. The microscope cannot be positioned outside the envelope of postural extension of the back and neck of the operator if the eyes are to remain on the eyepieces. Any movement of the microscope will induce a change in the head & neck and upper & lower back positions. The most practical way to use a microscope has been with the operator sitting in the 10 o'clock position. Sitting in this position forces the operator to tilt the microscope by rotating it clockwise to gain visual access to the patient's oral cavity, and subsequently tilting his/her head toward the right shoulder resulting in an unfavorable and strained postural neck position (the Taco neck position).

2. Muscle tension & pain: Assuming strained postural positions for extended periods of time cannot be avoided when performing clinical dental procedures under microscope magnification. This will result in discomfort, muscle contraction and pain. A strained visual postural position is further compounded by strenuous working positions resulting from the overextension of the arm holding the mouth mirror, and the forces required to stabilize it during use, either as a reflector, or as a retractor. This usually leads to shoulder and neck pain.

3. Assistant's co-observation tube moves: Tilting the microscope from side to side results in a greatly magnified vertical movement (up or down) at the eyepiece level of the co-observation tube. This renders the co-observation system useless or time-consuming to readjust to these fast-changing operating positions. In addition, sitting in the 10 o'clock position will place the assistant in the 1 o'clock position, an unfavorable location for an assistant.

The Solution:

The MORA Interface provides a solution to the problems listed above, by creating a "posture-friendly" microscope system. To obtain the maximum benefits from the MORA Interface, the operator must be seated in the 12 o'clock position. A microscope with a MORA Interface and a beam splitter increases the horizontal distance between the eyepieces and the long axis of the body of the microscope. It provides a horizontal working distance that is compatible with the distance between the top of the head and the mouth of the patient. This distance allows the operator to be seated in the 12 o'clock position, which can make the following possible:

1. Swinging the microscope body in a panning motion to the right and to the left sides of the mouth (25° in each direction), independent of the eyepieces. This way, the horizontal position of the eyepieces, and subsequently the operator's eyes remain unchanged and in constant position.

2. Panning the microscope body with ease due to the massive reduction in the weight of the moving parts when compared to moving the whole microscope. And because the center of rotation is located in the same plane as the planned rotation motion, the effort that goes into producing the rotation movement is intuitive and minimal.

3. Providing the assistant with the ability to sit in the 3 o'clock position and utilize a co-observation tube that can stay level.

4. Allowing the operator to sit in an upright position with an upright neck and eliminating the need to tilt the neck to the side.

5. Allowing the operator to equally extend the right and the left arms around the patient's head and thereby work more comfortably.

Eliminating the necessity to overextend one arm during a long procedure will minimize the muscle tension in the upper back.

6. Proper utilization of arm and wrist supports.

7. Giving the operator the ability to stabilize and control the patient's head movement.

Conclusion:

The MORA Interface can save your neck and upper back and can allow your assistant to use a co-observation tube. It makes working with a microscope more intuitive, more productive, and more enjoyable.



Dr. Assad F. Mora is a board-certified prosthodontist with a full-time restorative microdentistry practice in Santa Barbara, California, USA. He is a graduate of Indiana University, USA, with both DDS and MSD degrees. He is a pioneer in the field of restorative microdentistry and has been active in developing and inventing more user-friendly technology for microdentistry since 1992. Dr. Mora is the inventor of the MORA Interface. He has given presentations to numerous groups nationally and internationally. He is a contributor to the dental and patent literatures, and founder of the Institute of Microdentistry. Dr. Mora is a charter member and the Executive Director of the Academy of Microscope Enhanced Dentistry – AMED.

Dr. Mora can be reached at DrMora@microscopdentistry.com

The Microscope in Dentistry

An Editorial Forum for Dental Professionals

Published by:

Carl Zeiss Surgical GmbH
A Carl Zeiss Meditec Company
73447 Oberkochen
Germany
Commercial register: Ulm, HRB 501602,
USt.-IdNr. DE 814 227 537
President: Dr. Ludwin Monz

Editor-in-Chief:

Margit Krause-Bonte
Carl Zeiss Surgical GmbH

Responsible as defined by Paragraph 10 Section 3 of
the German Interstate Media Service Treaty (MDStV)

Editorial Board

Lisa DeLeon, Carl Zeiss Meditec, Inc.

Barbara von der Gathen-Zimmermann,
Carl Zeiss Surgical GmbH

Christian Nasdala, Carl Zeiss Surgical GmbH

Angelika Rieck, Carl Zeiss Surgical GmbH

surgical@meditec.zeiss.com
www.meditec.zeiss.com

Design & Layout:

Communication Services (S-KS), Carl Zeiss AG,
73447 Oberkochen, Germany

Printed by:

Druckwerk SÜD GmbH + Co. KG
88339 Bad Waldsee
88400 Biberach a. d. Riß
88239 Wangen i. Allgäu

© 2007 by Carl Zeiss Surgical GmbH
73447 Oberkochen, Germany
All rights reserved

OPMI and MediLive are registered trademarks
of Carl Zeiss.

If trademarks, trade names, technical solutions, etc. are
not explicitly mentioned, this does not mean that they
are not protected. The information in this magazine
only contains general descriptions or performance fea-
tures which do not always apply in the described form
in each individual application or which may change
during the course of further product development. The
desired performance features are only binding if they
have been expressly agreed upon in a signed contract.

Unless otherwise specified, the photos originate
from Carl Zeiss.

Permission for the reproduction of individual articles
and photos only after prior permission has been given
by the editors and with the appropriate reference to
the source.

